Seminar

Viral encephalitis: familiar infections and emerging pathogens

Richard J Whitley, John W Gnann

Significant advances have been made in our understanding of the natural history and pathogenesis of viral encephalitides. The development of PCR has greatly increased our ability to diagnose viral infections of the central nervous system, particularly for herpes and enteroviral infections. Advancing knowledge has led to the recognition that some encephalitides can be reliably prevented by vaccination (eg, Japanese encephalitis and rabies). For other pathogens such as the arboviruses, the focus has been on prevention by vector control. Finally, effective therapy has been established for a very limited number of viral infections (eg, aciclovir for herpes simplex encephalitis). Other potentially useful treatments, such as pleconaril for enteroviral meningoencephalitis are under clinical evaluation. We review current understanding of viral encephalitides with particular reference to emerging viral infections and the availibility of existing treatment regimens.

Introduction

Encephalitis is an unusual manifestation of human viral infection. Thus, whereas many individuals develop systemic viral infections, only a few develop symptomatic infection of the central nervous system (CNS). Viruses vary widely in their potential to produce significant CNS infection. For some viruses (eg, mumps), CNS infection is a common but a relatively benign part of the syndrome. For others (eg, Japanese encephalitis), neurological disease is the most prominent clinical feature of the systemic infection. A third group of viruses are those which commonly cause infection, but only rarely cause encephalitis (eg, herpes simplex virus [HSV]). Lastly, there are viruses for which human infection inevitably and exclusively results in CNS disease (eg, rabies). In addition to acute pathology, other viruses (eg, measles) can cause syndromes of post-infectious encephalopathy.

Pathogenesis

Access of viruses to the CNS can occur by either haematogenous or neuronal routes.[1–3] Haematogenous spread is most common and can result in an altered blood-brain barrier, as exemplified by arthropod-borne viral infections. After an insect bite with local viral replication in the skin, transient viraemia ensues with seeding of the reticuloendothelial system, and sometimes of muscle. With continued viral replication, secondary viraemia leads to infection of other organs, including the CNS. In acute viral encephalitis, capillary and endothelial inflammation of cortical vessels is a striking pathological finding, occurring primarily in the grey matter or grey-white junction. Perivascular lymphocytic infiltration results either from passive transfer of virus across the endothelium at pinocytotic junctions of the choroid plexus or active replication of virus in capillary endothelial cells. As disease progresses, astrocytosis and gliosis become prominent histopathological findings. Unique histopathological features include Cowdry type A intranuclear inclusions and Negri bodies that are associated with infections caused by herpesviruses and rabies virus, respectively.

Alternatively, viruses can access the nervous system by intraneuronal routes, as typically occurs with HSV. Data from both experimental models (rabbit and mouse) and human cases have suggested that the olfactory tract is one route of access of HSV to the brain. Data obtained by nucleic acid analysis of brain extracts suggest that HSV can exist in a latent state within the CNS.[4,5] Another example of intraneuronal transmission of virus to the CNS is rabies, with resulting limbic system involvement. Once the virus has reached the brain, subsequent replication can remain intraneuronal or can result in either cell-to-cell or extracellular spread.

Clinical manifestations

The clinical hallmark of acute viral encephalitis is a triad of fever, headache, and altered level of consciousness. Other common clinical findings include disorientation, behavioural and speech disturbances, and focal or diffuse neurological signs such as hemiparesis or seizures. These clinical findings distinguish a patient with encephalitis from one with viral meningitis, who can have headache, nuchal rigidity, and fever, but not altered sensorium or focal neurological findings.

Clinical findings reflect disease progression and the specific areas of CNS involvement, which is determined by the tropism of different viruses for different cell types. For example, polioviruses preferentially infect motor neurons, rabies virus selectively infects neurons of the limbic system, whereas mumps virus can infect epithelial cells of the choroid plexus. Infection of cortical neurons results in abnormal electrical activity and can be associated with seizures or focal deficits. Demyelination may follow destruction of oligodendroglia cells, whereas involvement of ependymal cells can result in hydranencephaly. The predilection of HSV for temporal lobe involvement, as illustrated in the figure, leads to clinical findings of aphasia, anosmia, temporal lobe seizures, and other focal abnormalities.

Search strategy and selection criteria

The material was found by searching Ovid and Medline databases using the terms "herpes simplex encephalitis", "viral encephalitis", "enteroviral infections", "Nipah viruses" and "polymerase chain reaction". The databases were searched in July, 2001

Lancet 2002; **359:** 507–14

Department of Pediatrics, Microbiology and Medicine (R J Whitley MD) **and Departments of Medicine and Microbiology** (J W Gnann MD)**, University of Alabama at Birmingham, 1600 7th Avenue South, ACC 616 Birmingham, Alabama, USA**

Correspondence to: Dr Richard J Whitley (e-mail: R.Whitley@peds.uab.edu)

For personal use. Only reproduce with permission from The Lancet Publishing Group.

Diagnosis

Establishing an aetiological diagnosis of a CNS viral infection may be difficult. Epidemiological features such as the season of year, prevalent diseases within the community, travel, recreational activities (eg, caving or hiking), occupational exposures, and animal contacts (eg, insect or animal bite) may provide helpful clues to the diagnosis. Late summer and early autumn are seasons when enteroviral infections are encountered in temperate climates. Similarly, during warm summer months, mosquito breeding may enhance the likelihood of transmission of arthropod-borne viruses.

Whereas physical examination of the patient does not usually result in an aetiological diagnosis, a few considerations are essential. For patients with acute viral encephalitis, the distinction between generalised and focal neurological findings is important. In a non-epidemic setting, the most common viral cause of focal encephalopathic findings is HSV.[6,7] However, when signs and symptoms of patients with biopsy-proven herpes simplex encephalitis are compared with those who did not have HSV CNS infection, there were no distinguishing clinical characteristics. Viruses that usually cause diffuse encephalitic diseases can, on occasion, localise to one area of the brain and mimic herpes simplex encephalitis,[7] as summarised in panel 1.

A distinction must be made between viral encephalitis and post-infectious encephalomyelitis. Post-infectious encephalomyelitis generally follows a non-specific viral syndrome, usually of the respiratory tract, and is most common in children. Neurological findings vary and reflect the areas of the brain involved. Demyelination is a prominent pathological finding. The distinction between post-infectious encephalomyelitis and acute viral encephalitis is crucial, since the management and prognosis are often quite different.

Evaluation of the cerebrospinal fluid (CSF) is essential, unless its collection is contraindicated because of high intracranial pressure. CSF abnormalities in patients with viral encephalitis generally include pleocytosis (predominately mononuclear cells) and increased levels of protein. A small percentage of patients (approximately 3 to 5%) with severe viral infections of the CNS (including herpes simplex encephalitis) can have completely normal CSF.[6] Cultures of CSF are of limited value for isolation of virus, but assays to detect viral antigens or nucleic acids may provide a rapid and specific diagnosis.

The use of neurodiagnostic tests including the electroencephalogram (EEG), computed tomographic (CT) scan, and magnetic resonance imaging (MRI) scan, can provide useful information in the assessment of encephalopathic patients. MRI seems to be a sensitive technique for detecting early changes in viral encephalitis.[8] The EEG is of value, particularly in patients with herpes simplex encephalitis in whom characteristic periodic high-voltage spike wave activity emanating from the temporal regions and slow-wave complexes at 2–3 s internals are highly suggestive of HSV infection.

Laboratory confirmation of the cause of brain infections provides therapeutic guidance for only a limited number of pathogens, but is always of prognostic value. For most diseases, antibodies identified in the CSF are not useful diagnostically unless measured quantitatively and sequentially. Routine assessment of acute and convalescence serum samples, to show either seroconversion or seroboosting, is of no practical value in the decision to institute therapy for viral encephalitis, but remains a useful tool for retrospective diagnosis for some infections (eg, arboviral encephalitis). The development of new diagnostic assays has simplified the diagnosis of viral infections of the brain. For example, an ELISA assay that detects IgM antibodies in CSF from patients with presumed Japanese encephalitis is both sensitive and specific, since most patients have antibodies at the time of admission to hospital and virtually all acquire them by day 3 of illness. Similarly, the use of PCR applied to CSF has become the diagnostic method of choice for many viral infections of the CNS, especially for those with herpesviruses and enteroviruses.

Effective vaccines for prevention of human encephalitis are available for a few viral pathogens (eg, rabies, Japanese encephalitis) and veterinary vaccines are available for others. For most zoonotic and arthropod-borne infections, vector control and avoiding bites remain the best available approaches to prevention. Specific antiviral therapy for viral encephalitis is generally limited to those diseases caused by herpesviruses. Treatment of viral encephalitis (eg, HSV, B virus) is complex, and practitioners should seek consultation with experts. Additional research to provide drugs for treatment of other viral pathogens (particularly RNA viruses) is urgently needed.

Panel 1: **Diseases that mimic herpes simplex encephalitis**

	Number of patients
Treatable diseases (n=46)	
Abscess or subdural empyema	5
Bacterial	1
Listeria	2
Fungal	2
Mycoplasma	6
Tuberculosis	3
Cryptococcal	2
Rickettsial	1
Toxoplasmosis	1
Mucormycosis	1
Meningococcal meningitis	1
Other viruses	4
Cytomegalovirus	3
Influenza A*	5
Echovirus infection*	2
Tumour	1
Subdural haematoma	6
Systemic lupus erythematosus	0
Adrenal leukodystrophy	0
Non-treatable diseases (n=49)	
Vascular disease	11
Toxic encephalopathy	5
Reye's syndrome	1
Viral (n=40)	7
Arbovirus infection	3
St Louis encephalitis	4
Western equine encephalitis	2
California encephalitis	8
Eastern equine encephalitis	0
Other herpesviruses	3
Epstein-Barr virus	1
Other viruses	1
Mumps virus	1
Adenovirus	2
Progressive multifocal leuko-encephalopathy (JC virus)	0
Lymphocytic choriomeningitis virus	0
Subacute sclerosing pan-encephalitis (measles virus)	0

*Drug therapy under investigation. Panel adapted from reference 7.

For personal use. Only reproduce with permission from The Lancet Publishing Group.

Selected clinical syndromes

Herpes simplex encephalitis

Human infection caused by HSV is ubiquitous, but encephalitis caused by this virus is uncommon. Nonetheless, herpes simplex encephalitis has played an important part in our understanding of viral infections of the CNS. Herpes simplex encephalitis was one of the first human infections to be routinely diagnosed using methods of molecular biology (ie, PCR for detection of HSV DNA in CSF).[9-13] Furthermore, herpes simplex encephalitis is one of the first viral infections to be successfully treated with antiviral chemotherapy.[14,15]

HSV is the most common cause of non-epidemic, acute focal encephalitis in the USA.[16] The estimated frequency of occurrence is one case per 250 000 to 500 000 population annually. Occurring throughout the year, about one-third of the cases of herpes simplex encephalitis develop in patients less than 20 years of age and one-half in individuals older than 50 years. In the absence of effective antiviral therapy, the mortality for this encephalitis is >70%, with only 2·5% of individuals returning to normal function.

Aciclovir is the treatment of choice for herpes simplex encephalitis, but morbidity and mortality remain high; mortality is 28% at 18 months after aciclovir treatment.[14,17] Age of the patient, level of consciousness at presentation, and duration of encephalitis all influence the outcome in patients receiving aciclovir therapy.[18] If the level of consciousness, as measured by the Glasgow coma score, is six or less, there is usually a poor outcome, irrespective of the age of the patient. If disease is present for 4 days or less, the likelihood of survival increases from 65% to 100% among aciclovir recipients. At 2 years after treatment, in this study 30% of aciclovir recipients were judged to be normal or mildly impaired, 9% had moderate sequelae, whereas 53% of the patients were dead or severely impaired. Relapse of HSV infection of the CNS after therapy has been shown. From studies of neonatal herpes simplex encephalitis, approximately 8% of babies who received aciclovir had a documented virological relapse if treated for 10 days at a dosage of 10 mg/kg every 8 h. Relapse has not been documented when higher doses[18] administered for 21 days are used. The exact percentage of adults and older children who have a relapse is unknown, but reports have suggested that relapse can occur after therapy and may be as high as 5%.[18]

A distinction must be made between HSV infections of the CNS that occur during the neonatal period and infections in older children and adults. Beyond the neonatal period, the majority of cases of herpes simplex encephalitis are attributable to HSV-1. On the basis of serological studies, about one-third of these cases are caused by primary HSV-1 infection and two-thirds result from viral reactivation.[19] Studies in animal models have shown reactivation of latent HSV from the trigeminal ganglia with transport of virus along nerves of the olfactory tract to the brain. The pathogenesis of HSV encephalitis in human beings is not well known. The possibility of reactivation of latent virus in brain tissue has not been excluded.

By contrast, neonates most commonly acquire HSV infection from virus shed in the maternal genital tract at the time of vaginal delivery. HSV-2 infection of the brain in newborn babies with multiorgan disseminated infection is likely to be blood-borne and associated with a diffuse encephalitis, resulting in generalised encephalomalacia. However, when disease involves only the CNS of the newborn baby, neuronal transmission of virus to the CNS initially results in unitemporal involvement that extends to bitemporal disease, as occurs in older children and adults (figure). Babies with HSV-1 infection of the CNS have a significantly better neurological outcome than those with HSV-2 infection. Recently, the use of a higher dose of aciclovir (20 mg/kg every 8 h) for 21 days has decreased mortality to 5% for newborn babies with HSV encephalitis; about 40% of survivors develop normally. The reasons for the differences in the pathogenesis and tropism of HSV-1 and HSV-2 CNS infections are not well understood.[20,21]

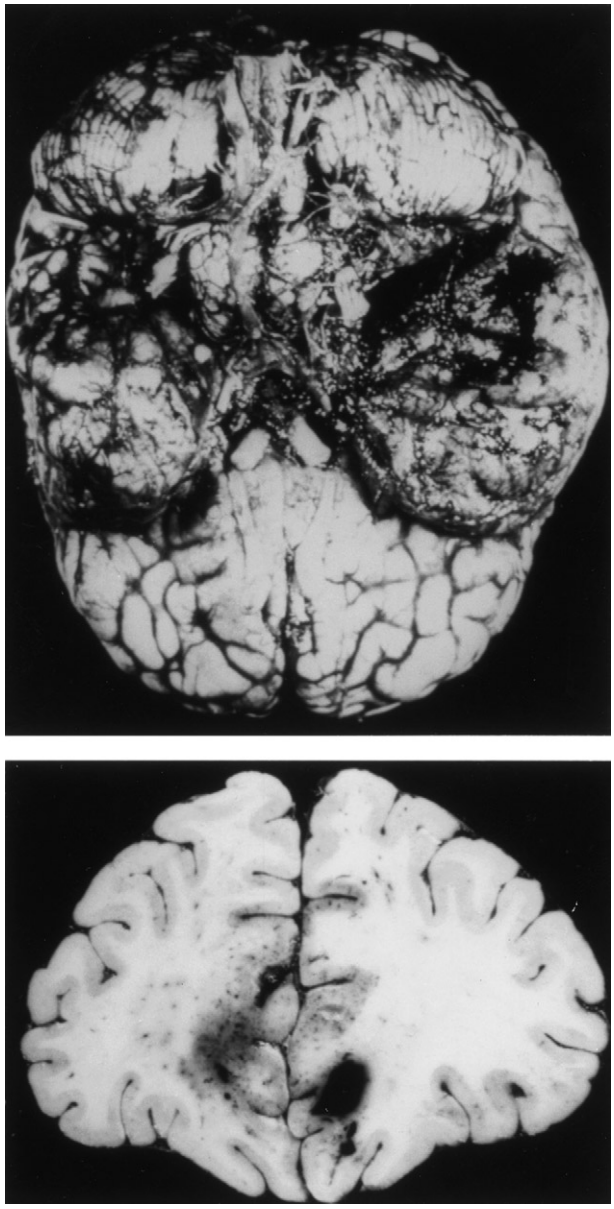

Coronal section of brain from patient with herpes simplex encephalitis

B virus

B virus (cercopithecine herpesvirus) causes enzootic infection of macaque monkeys that usually results in little or no disease in the animal.[22] However, B virus can cause severe and fatal encephalitis in human beings when transmitted by the bite or scratch of an infected macaque.[23,24] Human disease is characterised by a non-specific prodrome of fever and malaise (possibly with

For personal use. Only reproduce with permission from The Lancet Publishing Group.

herpetic blisters at the inoculation site), progressing to a rapidly ascending encephalomyelitis. The mortality rate for human encephalitis caused by B virus encephalitis is 50–70%. No evidence suggests that B virus can cause a subclinical infection in human beings.[25] Individuals who get a bite, scratch, or mucosal exposure from a potentially infected macaque should thoroughly decontaminate the wound. Prophylactic antiviral therapy is recommended for individuals who have a high-risk exposure.[26] Because of the high mortality rate associated with B virus encephalitis, patients should be treated with intravenous aciclovir or ganciclovir, although the therapeutic experience with this disease is limited.

Rabies

A zoonotic disease caused by a rhabdovirus, rabies remains one of the very few human infections with a near-100% mortality rate. Conversely, rabies can be readily prevented by judicious use of passive and active immunisation, even after infection has occurred.[27] In the less-developed world, infected dogs remain the primary vector for human rabies.[28] In the USA and western Europe, human infection is more likely due to exposure to bats or wild terrestrial mammals.[29] The incubation period for rabies in human beings can range from 5 days to greater than 6 months, although the usual period is 20–60 days.[30] After a prodromal period of fever, malaise, anxiety, and pain or itching at the site of the bite wound, patients with rabies develop overt CNS findings, which may be predominately encephalopathic or paralytic.[30] The patient progresses to coma, cardiorespiratory failure, and ultimately to death. Other than supportive care, no therapy for human rabies is available. The best diagnostic method for laboratory confirmation for rabies is detection of rabies virus RNA in saliva by reverse-transcriptase PCR, which has high sensitivity and specificity.[31,32] Alternative diagnostic methods include demonstration of rabies virus antigens in biopsy samples from the brain, nuchal skin, or corneal impressions. Medical management of rabies is focused on prevention. Veterinarians and other individuals at high-risk for exposure to rabies should receive pre-exposure vaccination. Unimmunised individuals who have a risky exposure to a potentially rabid animal should receive post-exposure vaccination with both rabies immunoglobulin (preferably human rather than equine rabies immunoglobulin) and rabies vaccine. Modern rabies vaccines produced in human tissue-culture cell lines or avian embryo cultures are more effective and much better tolerated than older vaccines produced in animal nervous tissues.[33]

Since 1996, several deaths have been reported in Queensland, Australia, from a rabies-like disease caused by Australia bat lyssavirus, which causes enzootic infection of flying foxes and other bats.[34,35] Pre-exposure or post-exposure administration of standard rabies vaccine seems to be protective against human infection with Australian bat lyssavirus.

Panel 2: **Arboviruses that cause encephalitis**

Virus	Vector	Geographical location
Togaviridae		
Alphavirus		
Eastern equine	Mosquitoes (Culiseta, Aedes)	Eastern and Gulf coasts of USA, Caribbean, and South America
Western equine	Mosquitoes (Culiseta, Culex)	Western USA and Canada
Venezuelan equine	Mosquitoes (Aedes, Culex, and others)	South and Central America, Florida and southwest USA
Flaviviridae		
West Nile complex		
St Louis	Mosquitoes (Culex)	Widespread in USA
Japanese	Mosquitoes (Culex)	Japan, China, Southeast Asia, and India
Murray Valley	Mosquitoes (Culex)	Australia and New Guinea
West Nile	Mosquitoes (Culex)	US, Africa, Europe, Middle East, and Asia
Ilheus	Mosquitoes (Psorophora)	South and Central America
Rocio	Mosquitoes (?)	Brazil
Tick-borne-complex		
Far Eastern	Ticks (Ixodes)	Eastern Russia
Central European	Ticks (Ixodes)	Central Europe
Kyasanur Forest	Ticks (Haemophysalis)	India
Louping-Ill	Ticks (Ixodes)	England, Scotland, and Northern Ireland
Powassan	Ticks (Ixodes)	Canada and northern USA
Negishi	Ticks (?)	Japan
Bunyaviridae		
Bunyavirus		
California	Mosquitoes (Aedes)	Western USA
La Crosse	Mosquitoes (Aedes)	Mid and eastern USA
Jamestown Canyon	Mosquitoes (Culiseta)	USA and Alaska
Snowshoe Hare	Mosquitoes (Culiseta)	Canada, Alaska, and northern USA
Tahyna	Mosquitoes (Aedes, Culiseta)	Czechoslovakia and Yugoslavia, Italy and southern France
Inkoo	Mosquitoes (?)	Finland
Phlebovirus		
Rift Valley	Mosquitoes (Culex, Aedes)	East Africa
Reoviridae		
Orbivirus		
Colorado tick fever	Ticks (Dermacentor)	Rocky mountains of USA

Adapted from reference 36.

For personal use. Only reproduce with permission from The Lancet Publishing Group.

Arthropod-borne encephalitis viruses

Viruses transmitted to human beings by the bites of arthropods (especially mosquitoes and ticks) are major causes of encephalitis worldwide (panel 2).[36] These encephalitides are predominately caused by viruses from the Togavirus (eg, eastern equine encephalitis), Flavivirus (eg, Japanese encephalitis) and Bunyavirus (eg, La Crosse encephalitis) families. An antigenically related group of Flaviviruses accounts for hundreds of thousands of cases of human infection worldwide each year. These include mosquito-borne diseases such as St Louis encephalitis (North America), Murray Valley encephalitis (Australia), West Nile virus encephalitis (Africa/Middle-East), and Japanese encephalitis (Asia), as well as far eastern tick-borne encephalitis (Russia) and western tick-borne encephalitis (Europe).[37]

Japanese encephalitis virus, transmitted by Culex spp mosquitoes, probably causes more cases of acute encephalitis than the other arthropod-borne viruses combined. During the past 75 years, from its focus in China and southeast Asia, Japanese encephalitis has expanded westward to India and Pakistan, northward to eastern Russia, eastward to the Philippines, and southward to Australia. In the northern region, epidemics of Japanese encephalitis can occur during the warm summer months, whereas disease occurs throughout the year in the warmer southern areas.[38] In China alone, at least 20 000 symptomatic cases are reported annually.[39] The ratio of symptomatic to symptomless infections is estimated to be 1:25 to 1:1000.[38] In areas where Japanese encephalitis is common, it is primarily a disease of children; however, more cases are seen in adults when the virus moves into a previously unexposed population. After a few days of non-specific symptoms, patients with Japanese encephalitis present with headache, vomiting, and altered mental state; seizures are reported in 85% of children and 10% of adults. Other characteristic findings include coarse tremor, dystonia, rigidity, and a characteristic mask-like facies. A variant that presents with poliomyelitis-like acute flaccid paralysis has recently been reported.[40] MRI shows a characteristic pattern of mixed intensity or hypodense lesions, especially in the thalamus, but also in basal ganglia and midbrain.[41] Diagnosis is facilitated by detection of IgM in CSF.[42] The mortality rate for patients admitted with Japanese encephalitis is about 30%. About 50% of survivors have severe neurological sequelae, including motor weakness, intellectual impairment, and seizure disorders. Therapy for Japanese encephalitis is limited to intensive supportive care. An effective formalin-inactivated vaccine is available and is recommended for inhabitants of endemic areas as well as travellers entering rural endemic areas.[43] An attenuated live virus vaccine has been developed in China, but is less widely available than the inactivated vaccine.[44]

In the USA, most cases of arthropod-borne encephalitis in recent years have been attributed to La Crosse virus, eastern equine encephalitis virus, and St Louis encephalitis virus (panel 3). La Crosse virus, a bunyavirus in the California encephalitis serogroup, causes aseptic meningitis and encephalitis, primarily in school-aged children. Although the mortality rate associated with La Crosse encephalitis is low, 10–15% of survivors will have significant neurological deficits.[45,46] Equine encephalitis virus occurs during the summer months along the eastern and Gulf coasts of the USA. By contrast with La Crosse encephalitis, it frequently occurs among older adults. Patients with eastern equine encephalitis have a short prodromal illness, then present with fever, headache, generalised seizures and may progress to stupor or coma.[47] MRI shows focal lesions in the basal ganglia, thalami, and brain stem. The mortality rate is 30–40% and at least one-third of survivors have significant neurological sequelae. High CSF white-blood cell count (>500/mm^3) and low serum sodium ($\leqslant$130 mmol/L) are associated with poor outcome.[47]

Beginning in August, 1999, an epidemic of viral encephalitis occurred in and around New York City that ultimately resulted in 62 cases and seven deaths. On the basis of positive serological results, the outbreak was initially attributed to St Louis encephalitis virus. However, a simultaneous epidemic of deaths among wild and exotic captive birds suggested that St Louis encephalitis virus (which does not ordinarily kill the avian host) might not be the correct pathogen. Ultimately, the causative agent was identified as West Nile virus.[48-50] West Nile virus encephalitis is a well-described disease in Africa and the Middle East, but had not previously been encountered in the western hemisphere. As a harbinger of the appearance of West Nile virus in North America, the first major epidemic in Europe occurred in Romania in 1996 and was characterised by a high rate of neurological complications.[51] Using hospital-based surveillance, 393 confirmed cases of this infection were identified in Romania, most of whom had meningoencephalitis. The mortality rate clearly increased with age; the overall fatality/case ratio was 4·3%, with all deaths occurring in

Panel 3: **Characteristics of selected mosquito-borne arbovirus encephalitides in the USA**

Virus	Geographical distribution	Age-group affected	Mortality	Sequelae symptoms
Western Equine	West, midwest USA	Infants and adults (>50 years old)	Moderate in infants; low in other ages	Headache, altered consciousness, seizures
Eastern Equine	East, Gulf Coast, southern USA	Children and adults	>30%	Headache, altered consciousness, seizures
Venezuelan	South America, southern USA	Adults	Rare	Headache, myalgia, pharyngitis
St Louis	Central, west, southern USA	Adults (>50 years old)	20%	Headache, nausea, vomiting, disorientation, stupor, irritability
La Crosse	Central, eastern USA	Children	10–15%	Seizures, paralysis, focal weakness
West Nile	East Coast USA, Africa, Middle East, Europe	Adults	Low	Seizures, myelitis, optic neuritis

Adapted from reference 37.

For personal use. Only reproduce with permission from The Lancet Publishing Group.

patients older than 50 years of age. The number of mild cases occurring in the Romanian population could not be calculated, but the overall seroprevalence rate was 4·1%. Clinical findings were similar in the Romanian and New York outbreaks. Patients typically presented with abrupt onset of fever, headache, neck stiffness, and vomiting. Patients who progressed to encephalitis showed depressed consciousness, disorientation, and generalised weakness. In both Romania and the USA, additional cases of West Nile virus infection appeared during the following summer, with geographical expansion of human and animal infections proving that West Nile viruses stayed alive during the winter and established an enzootic cycle of transmission involving birds and mosquitoes.[52,53] The pattern of recent epidemics of this virus in Europe and North America indicates that migratory birds contribute to dispersement of the virus, suggesting that it has the potential to cause new outbreaks.[54–56] In the summer of 2000, an unexpectedly large outbreak of West Nile virus encephalitis occurred in Israel, with more than 250 confirmed cases and 19 deaths, all in patients older than age 50 years.[57] There is currently no vaccine to prevent West Nile virus infection. Preventive measures include vector avoidance and mosquito control programmes.[58]

Enteroviral infections

Enteroviruses (including polioviruses, coxsackieviruses, and echoviruses) cause a wide spectrum of human diseases, including myocarditis and pericarditis, exanthems and enanthems, conjunctivitis, and meningitis, most of which are mild and self-limited. However, certain types of enteroviruses have the potential to cause severe and even fatal neurological disease, the best known of which is poliomyelitis. Other enteroviruses are frequent causes of seasonal aseptic meningitis and (less commonly) meningoencephalitis, especially in young infants. In 1998, a large outbreak of enteroviral infection (hand-foot-and-mouth disease and herpangina) occurred in Taiwan, with more than 60% of the cases attributed to enterovirus 71.[59] What distinguished this enteroviral epidemic from others was the high rate of neurological complications among children infected with enterovirus 71.[60] 405 patients with serious enteroviral infection were identified. Most were less than 5 years of age and the mortality rate in this group was 19·3%. Among patients with positive viral cultures, enterovirus 71 was isolated from 75% of patients admitted to hospital and from 92% of patients who died.[59] The typical clinical presentation was rhombencephalitis, characterised by myoclonus, tremors, ataxia, and cranial nerve involvement.[60] The most severely affected children presented with evidence of brain-stem involvement (including neurogenic shock and pulmonary oedema), which indicated a poor prognosis.[61] MRI indicated distinctive high-intensity lesions localised to the midbrain, pons, and medulla.[61] Long-term neurological sequelae were frequent among children with rhombencephalitis who survived. Although other outbreaks of enterovirus 71 disease have been reported, none have had the level of serious neurological involvement seen in the Taiwanese epidemic. There is currently no vaccine (other than for polio) or approved antiviral treatment of enteroviral infections, although the antiviral drug pleconaril shows promise and is currently undergoing clinical evaluation.[62]

New paramyxoviruses: Nipah and Hendra viruses

In 1997, an outbreak of encephalitis was noted among pig farm workers in Malaysia, but was attributed to Japanese encephalitis that recurred in September, 1998, and both clinical and epidemiological characteristics made it clear that Japanese encephalitis was not the correct diagnosis. A paramyxovirus isolated from a Malaysian patient with encephalitis showed in vitro characteristics similar to Hendra virus, a new morbillivirus previously isolated from horses and human beings in Australia in 1995.[63] Subsequent virological studies have shown that the Malaysian pathogen, now named Nipah virus, is closely related to, but distinct from, Hendra virus and that the two belong to a new genus within the family Paramyxoviridae.[64] Epidemiological investigations indicated that Nipah virus is transmitted to human beings by close contact with infected pigs, probably via the respiratory route.[65] The infection does not require an insect vector and is not readily transmitted from person-to-person. Patients with Nipah virus encephalitis present with fever, headache, dizziness, vomiting, and altered mental state.[65,66] Clinical features such as hypertension, tachycardia, absence of reflexes, and hypotonia suggest brain-stem involvement. MRI scanning shows a distinctive picture of discrete 2–7 mm lesions disseminated throughout the brain, but occurring mainly in the subcortical and deep white matter of the cerebral hemispheres.[67] Pathological correlation suggests that the lesions seen on MRI are due to widespread microinfarctions resulting from small vessel vasculitis.[68] Among 94 patients admitted to hospital with Nipah virus encephalitis in Malaysia from February to June, 1999, 32% died, 53% had full recovery, and 15% of survivors had persistent neurological deficits.[65] The epidemic was terminated by aggressive culling of all infected or exposed pigs. As with Hendra virus, the natural reservoir for Nipah virus appears to be pteropid bats, with pigs serving as hosts for viral amplification.[69]

Conclusion

Even before the medical community fully understood the pathogenesis, diagnosis, and management of familiar causes of viral encephalitis, emerging pathogens have made their presence known in alarming ways. The past 5 years have seen an outbreak of a deadly and previously unknown encephalitis virus (Nipah), dramatic extension of the range of a well-known arbovirus, and unexpected neurovirulence from a common paediatric pathogen (enterovirus 71). Each of these outbreaks suggests the high probability of future epidemics of encephalitis caused by previously unknown pathogens or new manifestations of known agents. The Nipah virus epidemic highlights the potential for amplification of zoonotic viruses when agricultural practices force huge numbers of animals into close quarters, creating an ideal environment for exchange of pathogens. The West Nile virus outbreak in the USA demonstrates how a pathogen can suddenly appear on the other side of the world. Although West Nile virus is naturally spread to new regions by migratory birds, there is at least the suspicion that the New York outbreak could have originated with illegal importation of infected birds. These scenarios suggest the need for clinicians to develop a broad differential diagnosis when assessing a new patient who presents with the acute onset of viral encephalitis.

Conflict of interest statement

J W Gnann receives funding from the Veteran Administration Hospitals. R J Whitley receives funding from the National Institute of Health.

Role of funding source

The sponsors of the study had no role in study design, data collection, data analysis, data interpretation, or writing of the report.

Acknowledgments

Studies done by the author and herein reported were initiated and supported under a contract (NO1-AI-65306, NO1-AI-15113,

For personal use. Only reproduce with permission from The Lancet Publishing Group.

NO1-AI-62554) with the Development and Applications Branch of the National Institute of Allergy and Infectious Diseases (NIAID), a Program Project Grant (PO1 AI 24009), by grants from the General Clinical Research Center Program (RR-032) and the State of Alabama.

References

1 Johnson RT. The pathogenesis of acute viral encephalitis and postinfectious encephalitis. *J Infect Dis* 1987; **155:** 359–64.
2 Johnson RT. Viral Infections of the Nervous System, 2nd edn. Philadelphia: Lippincott-Raven Publishers, 1998.
3 Johnson RT, Mims CA. Pathogenesis of viral infections of the nervous system. *N Engl J Med* 1968; **278:** 23–30, 84–92.
4 Baringer JR, Pisani P. Herpes simplex virus genomes in human nervous system tissue analyzed by polymerase chain reaction. *Ann Neurol* 1994; **36:** 823–29.
5 Jamieson GA, Maitland NJ, Wilcock GK, Craske J, Itzhaki RF. Latent herpes simplex virus type 1 in normal and Alzheimer's disease brains. *J Med Virol* 1991; **33:** 224–27.
6 Whitley RJ, Tilles J, Linneman C Jr, et al. Herpes simplex encephalitis: clinical assessment. *JAMA* 1982; **247:** 317–20.
7 Whitley RJ, Cobbs CG, Alford CA Jr, et al. Diseases that mimic herpes simplex encephalitis: diagnosis, presentation and outcome. *JAMA* 1989; **262:** 234–39.
8 Domingues RB, Fink MC, Tsanaclis SM, et al. Diagnosis of herpes simplex encephalitis by magnetic resonance imaging and polymerase chain reaction assay of cerebrospinal fluid. *J Neurol Sci* 1998; **157:** 148–53.
9 Rowley A, Lakeman F, Whitley R, Wolinsky S. Rapid detection of herpes simplex virus DNA in cerebrospinal fluid of patients with herpes simplex encephalitis. *Lancet* 1990; **335:** 440–41.
10 Boerman RH, Arnoldus EP, Raap AK. Polymerase chain reaction and viral culture techniques to detect HSV in small volumes of cerebrospinal fluid; an experimental mouse encephalitis study. *J Virol Methods* 1989; **25:** 189–97.
11 Puchhammer-Stockl E, Popow-Kraupp T, Heinz FX, Mandl CW, Kunz C. Establishment of PCR for the early diagnosis of herpes simplex encephalitis. *J Med Virol* 1990; **32:** 77–82.
12 Lakeman FD, Whitley RJ, the National Institute of Allergy and Infectious Diseases Collaborative Antiviral Study Group. Diagnosis of herpes simplex encephalitis: application of polymerase chain reaction to cerebrospinal fluid from brain biopsied patients and correlation with disease. *J Infect Dis* 1995; **172:** 857–63.
13 Powell KF, Anderson NE, Frith RW, Croxson MC. Non-invasive diagnosis of herpes simplex encephalitis. *Lancet* 1990; **335:** 357–58.
14 Whitley RJ, Alford CA, Jr., Hirsch MS, et al. Vidarabine versus acyclovir therapy in herpes simplex encephalitis. *N Engl J Med* 1986; **314:** 144–49.
15 Longson M, Klapper PE, Cleator GM. The treatment of herpes encephalitis. *J Infect* 1983; **6:** 15–16.
16 Whitley RJ, Lakeman F. Herpes simplex infections of the central nervous system: therapeutic and diagnostic considerations. *Clin Infect Dis* 1995; **20:** 414–20.
17 McGrath N, Anderson NE, Croxson MC, Powell KF. Herpes simplex encephalitis treated with acyclovir: diagnosis and long term outcome. *J Neurol Neurosurg Psychiatry* 1997; **63:** 321–26.
18 Ito Y, Kimura H, Yabuta Y, et al. Exacerbation of herpes simplex encephalitis after successful treatment with acyclovir. *Clin Infect Dis* 2000; **30:** 185–87.
19 Whitley RJ. Herpes simplex virus. In: Scheld WM, Whitley RJ, Durack DT, eds. Infections of the Central Nervous System. Philadelphia: Lippincott-Raven, 1996: 73–89.
20 Vahlne A, Svennerholm B, Sandberg M, Hamberger A, Lycke E. Differences in attachment between herpes simplex type 1 and type 2 viruses to neurons and glial cells. *Infect Immun* 1980; **28:** 675–80.
21 Gerber SI, Belval BJ, Herold BC. Differences in the role of glycoprotein C of HSV-1 and HSV-2 in viral binding may contribute to serotype differences in cell tropism. *Virology* 1995; **214:** 29–39.
22 Jainkittivong A, Langlais RP. Herpes B virus infection. *Oral Surg Oral Med Oral Pathol Oral Radiol Endod* 1998; **85:** 399–403.
23 Centers for Disease Control and Prevention. Fatal Cercopithecine herpesvirus 1 (B virus) infection following a mucocutaneous exposure and interim recommendations for worker protection. *MMWR Morb Mortal Wkly Rep* 1998; **47:** 1073–76.
24 Ostrowski SR, Leslie MJ, Parrott T, Abelt S, Piercy PE. B virus from pet macaque monkeys: an emerging threat in the United States? *Emerg Infect Dis* 1998; **4:** 117–21.
25 Freifeld AG, Hilliard J, Southers J, et al. A controlled seroprevalence survey of primate handlers for evidence of asymptomatic herpes B virus infection. *J Infect Dis* 1995; **171:** 1031–34.
26 Holmes GP, Chapman LE, Stewart JE, et al. Guidelines for preventing and treating B virus infections in exposed persons. *Clin Infect Dis* 1995; **20:** 421–39.
27 Moran GJ, Talan DA, Mower W, et al. Appropriateness of rabies postexposure prophylaxis treatment for animal exposures. Emergency ID Net Study Group. *JAMA* 2000; **284:** 1001–07.
28 Anonymous. World survey of rabies, 1997. *Wkly Epidemiol Rec* 1997; **74:** 381–84.
29 Krebs JW, Smith JS, Rupprecht CE, Childs JE. Rabies surveillance in the United States during 1998. *J Am Vet Med Assoc* 2000; **215:** 1786–98.
30 Plotkin SA. Rabies. *Clin Infect Dis* 2000; **30:** 4–12.
31 Hanlon CA, Smith JS, Anderson GR. Recommendation of a national working group on prevention and control of rabies in the United States. Article II: Laboratory diagnosis of rabies. The National Working Group on Rabies Prevention and Control. *J Am Vet Med Assoc* 1999; **215:** 1444–46.
32 Noah DL, Drenzek CL, Smith JS, et al. Epidemiology of human rabies in the United States, 1980 to 1996. *Ann Intern Med* 1998; **128:** 922–30.
33 Centers for Disease Control and Prevention. Human Rabies Prevention - United States, 1999. *MMWR Morb Mortal Wkly Rep* 1999; **48** (suppl RR-1)**:** S1–21.
34 Hanna JN, Carney IK, Smith GA, et al. Australian bat lyssavirus infection: a second human case with a long incubation period. *Med J Aust* 2000; **172:** 597–99.
35 Samaratunga H, Searle JW, Hudson N. Non-rabies Lyssavirus human encephalitits from fruit bats: Australian bat Lyssavirus (pteropid Lyssavirus) infection. *Neuropathol Appl Neurobiol* 1998; **24:** 331–35.
36 Griffin DE. Viral infections of the central nervous system. In: Galasso GJ, Whitley RJ, Merigan TC, eds. Antiviral Agents and Viral Diseases of Man. New York: Raven Press, 1990: 461–95.
37 Whitley RJ. Viral encephalitis. *N Engl J Med* 1990; **323:** 242–50.
38 Solomon T, Dung NM, Kneen R, Gainsborough M, Vaughn DW, Khanh VT. Japanese encephalitis. *J Neurol Neurosurg Psychiatry* 2000; **68:** 405–15.
39 Vaughn DW, Hoke CH, Jr. The epidemiology of Japaense encephalitis: prospects for prevention. *Epidemiol Rev* 1992; **14:** 197–221.
40 Solomon T, Kneen R, Dung NM, et al. Poliomyelitis-like illness due to Japanese encephalitis virus. *Lancet* 1998; **351:** 1094–97.
41 Kalita J, Mista UK. Comparison of CT scan and MRI findings in the diagnosis of Japanese encephalitis. *J Neurol Sci* 2000; **174:** 3–8.
42 Solomon T, Thao LT, Dung NM, et al. Rapid diagnosis of Japanese encephalitis by using an immunoglobulin M dot enzyme immunoassay. *J Clin Microbiol* 1998; **36:** 2030–34.
43 Centers for Disease Control and Prevention. Inactivated Japanese encephalitis virus vaccine. Recommendations of the Advisory Commitee on Immunization Practices (ACIP). *MMWR Morb Mortal Wkly Rep* 1993; **42:** 1–15.
44 Tsai TF, Yu YX, Jia LL, et al. Immunogenicity of live attenuated SA14–14–2 Japanese encephalitis vaccine—a comparison of 1– and 3–month immunization schedules. *J Infect Dis* 1998; **177:** 221–23.
45 McJunkin JE, de los Reyes EC, Irazuzta JE, et al. La Crosse encephalitis in children. *N Engl J Med* 2001; **344:** 801–07.
46 McJunkin JE, Khan RR, Tsai TF. California-LaCrosse encephalitis. *Infect Dis Clin North Am* 1998; **12:** 83–93.
47 Deresiewicz RL, Thaler SJ, Hsu L, Zamani AA. Clinical and neuroradiographic manifestations of eastern equine encephalitis. *N Engl J Med* 1997; **336:** 1867–74.
48 Centers for Disease Control and Prevention. Outbreak of West Nile-like viral encephalitis—New York, 1999. *MMWR Morb Mortal Wkly Rep* 1999; **48:** 845–49.
49 Briese T, Jia XY, Huang C, Grady LJ, Lipkin WI. Identification of a Kunjin/West Nile-like flavivirus in brains of patients with New York encephalitis. *Lancet* 1999; **354:** 1261–62.
50 Jia XY, Briese T, Jordan I, et al. Genetic analysis of West Nile New York 1999 encephalitis virus. *Lancet* 1999; **354:** 1971–72.
51 Tsai TF, Popovici F, Cernescu C, Campbell GL, Nedelcu NI. West Nile encephalitis epidemic in southeastern Romania. *Lancet* 1998; **352:** 767–71.
52 Cernescu C, Nedelcu NI, Tardei G, Ruta S, Tsai TF. Continued transmission of West Nile virus to humans in southeastern Romania, 1997–1998. *J Infect Dis* 2000; **181:** 710–12.
53 Centers for Disease Control and Prevention. Human West Nile virus surveillance—Connecticut, New Jersey, and New York, 2000. *MMWR Morb Mortal Wkly Rep* 2001; **50:** 265–68.
54 Hubalek Z, Halouzka J. West Nile fever—a reemerging mosquito-borne viral disease in Europe. *Emerg Infect Dis* 1999; **5:** 643–50.
55 Lanciotti RW, Roehrig JT, Deubel V, et al. Origin of West Nile virus responsible for an outbreak on encephalitis in the northeastern United States. *Science* 1999; **286:** 2333–37.

For personal use. Only reproduce with permission from The Lancet Publishing Group.

56 Rappole JH, Derrickson SR, Hubalek Z. Migratory birds and spread of West Nile virus in the Western Hemisphere. *Emerg Infect Dis* 2000; **6:** 319–28.
57 Siegel-Itzkovich J. Twelve die of West Nile virus in Israel. *BMJ* 2000; **321:** 724.
58 Centers for Disease Control and Prevention. Guidelines for surveillance, prevention, and control of West Nile virus infection—United States. *MMWR Morb Mortal Wkly Rep* 2000; **49:** 25–28.
59 Ho M, Chen ER, Hsu KH, et al. An epidemic of enterovirus 71 infection in Taiwan. Taiwan Enterovirus Epidemic Working Group. *N Engl J Med* 1999; **341:** 929–35.
60 Huang CC, Liu CC, Chang YC, Chen CY, Wang ST, Yeh TE. Neurologic complications in children with enterovirus 71 infection. *N Engl J Med* 1999; **341:** 936–42.
61 Wang SM, Liu CC, Tseng HW, et al. Clinical spectrum of enterovirus 71 infection in children in southern Taiwan, with an emphasis on neurological complications. *Clin Infect Dis* 1999; **29:** 184–90.
62 Pevear DC, Tull TM, Seipel ME, Groarke JM. Activity of pleconaril against enteroviruses. *Antimicrob Agents Chemother* 1999; **43:** 2109–115.
63 Selvey LA, Wells RM, McCormack JG, et al. Infection of humans and horses by a newly described morbillivirus. *Med J Aust* 1995; **162:** 642–45.
64 Chua KB, Bellini WJ, Rota PA, et al. Nipah virus: a recently emergent deadly paramyxovirus. *Science* 2000; **288:** 1432–435.
65 Goh KJ, Tan CT, Chew NK, et al. Clinical features of Nipah virus encephalitis among pig farmers in Malaysia. *N Engl J Med* 2000; **342:** 1229–35.
66 Paton NI, Leo YS, Zaki SR, et al. Outbreak of Nipah-virus infection among abattoir workers in Singapore. *Lancet* 1999; **354:** 1253–56.
67 Sarji SA, Abdullah BJ, Goh KJ, Tan CT, Wong KT. MR imaging features of Nipah encephalitis. *Am J Roentgenol* 2000; **175:** 437–42.
68 Chua KB, Goh KJ, Wong KT, et al. Fatal encephalitis due to Nipah virus among pig-farmers in Malaysia. *Lancet* 1999; **354:** 1257–59.
69 Enserink M. Emerging diseases. Malaysian researchers trace Nipah virus outbreak to bats. *Science* 2000; **289:** 518–19.

Uses of error

Retreat

Paul Durrington

I was a house physician in the gastroenterology unit of a teaching hospital, when a novice monk, 20 years of age, was transferred for further investigation of haematemesis. Nurses reported that he vomited blood and produced bedpans containing faeces and fresh blood. The patient was shy and unassuming. He generally went to the bathroom alone in order to avoid burdening the nurses, who were busy with what he considered more deserving cases. Sometimes he was discovered stoically attempting to clear up the blood himself. He continued to be exposed to an ever-increasing array of medical investigations. Meanwhile, my house job was not going too well. Results of many blood tests, which it was my duty to perform, never seemed to arrive, despite the fact that I had dispatched samples and requests. Senior colleagues were beginning to question my integrity. I put all the blood samples and request forms into a large basket just outside the ward which the porter emptied on a regular basis. A curious hypothesis occurred to me. I waited until the patient produced another bedpan with a formed motion sitting beside a pool of blood. I took some of this blood personally to the laboratory. It was a different ABO blood group to that of the patient, who, after a somewhat heated conversation with the professor of medicine, disappeared before the professor of psychiatry arrived. To be slick, of course, I could report this as the first example of a genetic test to diagnose one of the syndromes (haematemesis merchant) described by Richard Asher in his wonderful article on Munchausen's syndrome. In fact it was an example of how bad most of us are at diagnosing functional illness; a failing which I suspect is becoming worse rather than better as we retreat into our various specialties and the investigations available to us multiply.

Department of Medicine, Manchester Royal Infirmary, Manchester M13 9WL, UK (Prof P Durrington FRCP)

For personal use. Only reproduce with permission from The Lancet Publishing Group.