Heart Valve Disease

Adam S. Helms, MD[a,*], David S. Bach, MD[b]

KEYWORDS

• Aortic stenosis • Mitral regurgitation • Heart valve disease • Valve lesion

KEY POINTS

- Soft (1–2/6) midsystolic murmurs at the upper sternal border that do not increase with Valsalva maneuver and are not associated with cardiac symptoms do not require further testing; all other murmurs warrant echocardiography for further evaluation.
- The presence of symptoms (usually dyspnea) caused by a severe valve lesion is almost always an indication for valve intervention.
- Patients with valve disease should be educated about symptoms that may be attributable to their valve lesion and that the development of symptoms is a reason for immediate clinical evaluation.
- Asymptomatic patients with severe valve disease may warrant surgical intervention if lesion-specific guideline criteria of ventricular remodeling are met, determined primarily from echocardiography.
- Echocardiography provides invaluable information in nearly all cases of valve disease, but inherent limitations in determining the precise severity of valve disease mandate careful clinical correlation.

INTRODUCTION

Heart valve disease is most often characterized by a prolonged asymptomatic period that lasts for years and presents primary care physicians with an opportunity to detect disease before irreversible heart failure or other cardiac complications develop. Alternatively, acute valvular disease can masquerade as a respiratory illness or present with nonspecific systemic symptoms, and an astute physical examination by a primary care physician can quickly direct appropriate urgent care. Therefore, an understanding of the common pathologies and presentations of valvular heart disease is critical. This review focuses on the 2 most common valve lesions, aortic stenosis and mitral regurgitation, in addition to providing an overview of other valve disease topics.

[a] Department of Internal medicine, University of Michigan Health System, Medical Science Research Building III, 1150 West Medical Center Drive, Room 7301, Ann Arbor, MI 48109-5644, USA; [b] Department of Internal medicine, University of Michigan, 1500 East Medical Center Drive, CVC Room 2147, SPC 5853, Ann Arbor, MI 48109-5853, USA
* Corresponding author.
E-mail address: adamhelm@med.umich.edu

Prim Care Clin Office Pract 40 (2013) 91–108
http://dx.doi.org/10.1016/j.pop.2012.11.005 primarycare.theclinics.com
0095-4543/13/$ – see front matter © 2013 Elsevier Inc. All rights reserved.

PHYSICAL EXAMINATION

Cardiac auscultation can reveal a multitude of insights regarding the nature and severity of heart valve disease. In the modern era, however, the most important point is to identify which auscultatory signs are indicative of pathology and warrant more definitive investigation with echocardiography versus those that require no further testing. During auscultation, special care should be given to discriminating systolic murmurs, which may or may not need further evaluation, from diastolic murmurs, which always warrant echocardiographic imaging. The carotid pulse should be palpated to confirm the diastolic versus systolic timing of the murmur. In general, a soft (1–2/6) midsystolic murmur at the upper sternal border that does not increase with Valsalva maneuver does not require further testing in the absence of cardiac symptoms.[1]

Common characteristic murmurs are reviewed in **Table 1**. Other key findings on physical examination that should usually lead to echocardiographic imaging include elevation of the jugular venous pressure, rales, peripheral edema, hepatomegaly, abdominal distension, peripheral edema, and widened pulse pressure.

AORTIC STENOSIS

Causes

Aortic stenosis is the most commonly encountered valve lesion. The primary cause is either bicuspid aortic valve or calcific degeneration in the elderly, with only a small

Table 1
Common murmurs and auscultatory characteristics

Cardiac Pathology	Murmur Characteristics
Physiologic flow murmur	1–2/6 Early- to mid-peaking systolic murmur at the upper sternal border that does not change with Valsalva maneuver
Aortic stenosis	≥3/6 Mid- to late-peaking murmur at the right upper sternal border with diminished second heart sound and decreased carotid upstroke
Aortic insufficiency	Early, soft decrescendo diastolic murmur at the right upper sternal border best heard leaning forward with end-expiratory breath hold
Mitral stenosis	Low-pitched, soft, rumbling mid–late diastolic murmur at the apex, sometimes with associated early diastolic opening snap
Mitral regurgitation	Variable intensity blowing systolic murmur at the apex that may be holodiastolic and can radiate to the sternal border, axilla, or back. If due to mitral valve prolapse, may increase with Valsalva and squat-to-stand maneuvers and may be late systolic (after a click).
Hypertrophic obstructive cardiomyopathy	Mid- to late-peaking systolic murmur at the right sternal border that increases with Valsalva or squat-to-stand maneuvers.

Data from American College of Cardiology/American Heart Association Task Force on Practice Guidelines, Society of Cardiovascular Anesthesiologists, Society for Cardiovascular Angiography and Interventions, Society of Thoracic Surgeons, Bonow RO, Carabello BA, Kanu C, et al. ACC/AHA 2006 guidelines for the management of patients with valvular heart disease: a report of the American College of Cardiology/American Heart Association Task Force on Practice Guidelines (writing committee to revise the 1998 Guidelines for the Management of Patients With Valvular Heart Disease): developed in collaboration with the Society of Cardiovascular Anesthesiologists: endorsed by the Society for Cardiovascular Angiography and Interventions and the Society of Thoracic Surgeons. Circulation 2006;114(5):e84–231.

minority of cases due to rheumatic heart disease or congenital (nonbicuspid) aortic stenosis.

Bicuspid Aortic Valve

Patients with a bicuspid aortic valve typically present in middle age but can present at any time from infancy to advanced age. The bicuspid valve can be due to either the formation of only 2 sinuses of Valsalva at the root of the aorta or a lack of separation of 2 of the 3 leaflets during cardiac development (**Fig. 1**). Clinically, however, these entities carry the same risk of complications and are managed the same way. Although the genetic underpinnings of the bicuspid aortic valve are not yet fully elucidated, direct evidence of heritability has been demonstrated, warranting clinical screening of first-degree relatives.[2]

The primary complications and associated conditions related to bicuspid aortic valve are

- Aortic stenosis (most common)
- Aortic insufficiency
- Aortic valve endocarditis
- Aortic aneurysm and dissection
- Concurrent aortic coarctation (upper extremity hypertension in a young person with a bicuspid valve is strongly suggestive)

The presenting symptoms of a bicuspid aortic valve are dependent on the specific complication affecting the valve. In addition to follow-up of the valve disease, screening for an ascending aortic aneurysm is critical (annual echocardiography generally is adequate if the ascending aorta is well visualized) as is as screening for aortic coarctation (thoracic CT or MRI) if hypertension or diminished lower extremity pulses are present.[1] Aortic aneurysm is now understood to be due to a concomitant connective tissue pathology and not poststenotic dilation. Therefore, this screening should take place regardless of the presence of aortic stenosis.

Calcific Aortic Valve

Calcific aortic stenosis typically presents in older individuals (ages 70–90 years) and affects 2.6% of the population over age 75.[3] The course of aortic stenosis is inevitably

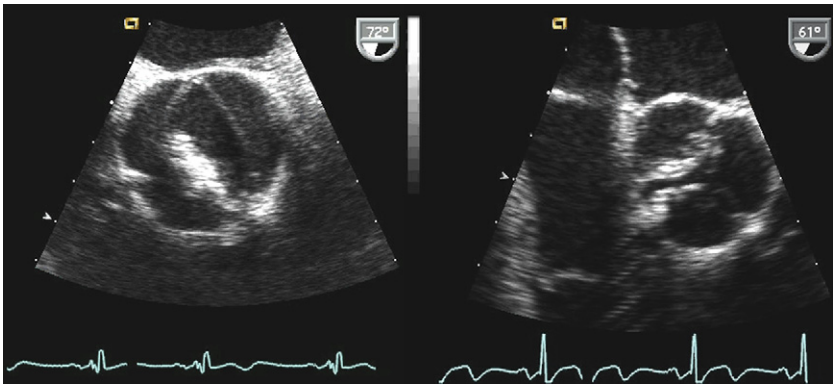

Fig. 1. Transesophageal echocardiographic images demonstrate (*left*) a bicuspid aortic valve with 2 equal aortic valve cusps and a central, ellipsoid-shaped opening, with moderate aortic stenosis and (*right*) a tricuspid aortic valve with heavy calcification and restricted opening consistent with severe aortic stenosis.

progressive, with an average narrowing of the valve area by 0.1 cm^2 per year; progression may be more rapid, particularly in the presence of heavy aortic valve calcification or aortic regurgitation (see **Fig. 1**).[4–7]

Presentation and Natural History

Aortic stenosis may present with either an isolated murmur on routine cardiac examination (see **Table 1**) or 1 or more of the following symptoms:

- Angina (due to subendocardial demand ischemia)
- Syncope (typically exertional, due to inability to augment cardiac output)
- Heart failure

These symptoms do not occur until aortic stenosis is severe. An absence of symptoms typically is associated with a low risk of cardiac complications. The development of symptoms in the presence of severe aortic stenosis, however, heralds a dramatic increase in mortality, with an average survival of only 2 to 3 years and a substantial mortality rate from sudden death.[8–10]

Grading Aortic Stenosis Severity

Accurate grading of aortic stenosis is both highly important and often difficult. The physical examination remains of great value, because clinical evidence of severe aortic stenosis (late-peaking murmur, diminished carotid pulse, and diminished second heart sound) should always prompt clinicians to be skeptical of diagnostic testing that may underestimate the true severity. Nonetheless, echocardiography has proved an extremely useful tool for grading the severity of aortic stenosis. The ability to visualize the stenotic valve as well as measure blood flow velocity (used to calculate both pressure gradients and valve area) allows stratification of stenosis severity in most cases. Common pitfalls of echocardiography include underestimation of the gradients and overestimation of the valve area if the ultrasound beam is not aligned parallel to the stenotic jet and underestimation or overestimation of the valve area if the left ventricular (LV) outflow tract is not accurately measured.[11] In the occasional case when the clinical presentation and echocardiography results are discrepant, cardiac catheterization can be performed for direct pressure measurements. Routine cardiac catheterization is no longer needed, however, in the majority of cases.[1] Adjunctive testing with transesophageal echocardiography, CT, or cardiac MRI may be useful in select cases for clearer visualization of the valve orifice.

Management of Aortic Stenosis

No medication has proved to have an impact on the progression of or adverse prognosis associated with aortic stenosis. Initial enthusiasm for statin therapy to slow progression of calcific aortic stenosis was tempered by the negative simvastatin and ezetimibe in aortic stenosis (SEAS) trial, which showed no benefit of lipid lowering with simvastatin and ezitimibe in patients with mild or moderate aortic stenosis.[12] Although some speculation remains that earlier up-front statin therapy in aortic sclerosis might be of benefit, no prospective evidence supports this practice.

The most important aspect of management is the timing of valve replacement surgery. Because bioprosthetic tissue valves uniformly undergo structural degeneration (ranging from approximately 50% degeneration rate by 10 years in individuals less than 45 years of age to approximately 10%–20% by 15 years in individuals greater than 65 years of age) and mechanical valves require lifelong anticoagulation with warfarin, a valve replacement is not really a cure, but an exchange of one disease for another chronic medical condition.[1] Although surgery should not be performed

too early, waiting too long places patients at excessive risk for sudden death or irreversible cardiomyopathy. The timing of intervention can require significant clinical judgment, and consultation with a specialist in heart valve disease is reasonable for any patient with significant aortic stenosis.

Although cardiology referral is appropriate for moderate or severe aortic stenosis, primary care physicians, who often have a closer relationship with patients than the subspecialist, continue to have a critical role in the surveillance for symptomatic progression. Patients must be reminded of these symptoms at each visit. Echocardiography plays a pivotal role in follow-up to verify that LV size and function remain normal. **Table 2** summarizes recommendations for routine follow-up.

The American College of Cardiology (ACC)/American Heart Association (AHA) class I and class IIA indications for surgery for aortic stenosis include the following[1]:

- Severe aortic stenosis with symptoms of angina, syncope, or dyspnea (class I recommendation)
- Severe aortic stenosis and LV systolic dysfunction (ejection fraction $\leq$50%)
- Severe (class I) or moderate (class IIA recommendation) aortic stenosis and cardiac surgery for another reason (bypass surgery, aorta surgery, or other valve surgery)

Additional class IIB (lower level of evidence) recommendations include asymptomatic aortic stenosis that is very severe (eg, aortic valve area $\leq$0.6 cm^2), is rapidly progressing ($\geq$0.3 cm^2 decrease in valve area over 12 months), or is associated with symptoms on exercise stress testing. Among 116 patients in a prospective trial, 5% of patients with asymptomatic but very severe aortic stenosis died suddenly in a median follow-up period of approximately 3 years.[14] One prospective but nonrandomized study has shown a potential survival benefit for very severe aortic stenosis with early aortic valve replacement before symptoms develop.[15]

Role of Exercise Testing in Asymptomatic Severe Aortic Stenosis

Patients with long-standing heart valve disease may become accustomed to slowly progressive functional limitation imposed by the transition to severe disease and

Table 2
Recommended follow-up intervals for aortic stenosis

Severity	Recommended Follow-up[13]
Mild	Clinic evaluation and echocardiogram every 3–5 y
Moderate	Clinic evaluation every 1 y; echocardiogram every 1–2 y
Severe	Annual clinic evaluation and echocardiogram; increase to 3–6 mo intervals if rapid progression or nearing surgical indication

Data from American College of Cardiology Foundation Appropriate Use Criteria Task Force, American Society of Echocardiography, American Heart Association, American Society of Nuclear Cardiography, Heart Failure Society of America, Heart Rhythm Society, Society for Cardiovascular Angiography and Interventions, Society of Critical Care Medicine, Society of Cardiovascular Computed Tomography, Society for Cardiovascular Magnetic Resonance, Douglas PS, Garcia MJ, Haines DE, et al. ACCF/ASE/AHA/ASNC/HFSA/HRS/SCAI/SCCM/SCCT/SCMR 2011 Appropriate Use Criteria for Echocardiography. A Report of the American College of Cardiology Foundation Appropriate Use Criteria Task Force, American Society of Echocardiography, American Heart Association, American Society of Nuclear Cardiology, Heart Failure Society of America, Heart Rhythm Society, Society for Cardiovascular Angiography and Interventions, Society of Critical Care Medicine, Society of Cardiovascular Computed Tomography, and Society for Cardiovascular Magnetic Resonance endorsed by the American College of Chest Physicians. J Am Coll Cardiol 2011;57(9):1126–66.

consequently not report symptoms despite a decline in functional status. In patients with clear evidence of severe aortic stenosis and no symptoms, there is a role for symptom-limited exercise testing, under direct cardiologist supervision, to verify that exercise capacity remains appropriate for age and that symptoms of aortic stenosis do not appear at an inappropriately low level of exercise. The role of exercise stress testing is limited to patients with asymptomatic valvular disease without a conventional indication for surgery; symptomatic aortic stenosis is a contraindication for exercise testing. Patients should be carefully monitored and the intensity of exercise protocol tailored to the functional status of each patient. Exercise testing for asymptomatic severe aortic stenosis has been demonstrated as safe if appropriately performed and of potential prognostic benefit if positive.[16,17] Although the European Society of Cardiology supports exercise testing in their diagnostic algorithm for severe asymptomatic aortic stenosis, the current ACC/AHA guidelines for valvular heart disease support only a class IIB recommendation for exercise testing.[1,18] The authors have adopted a practice of annual supervised symptom-limited exercise stress testing in patients with asymptomatic severe aortic stenosis who otherwise do not meet indications for aortic valve replacement.

Surgical Risk Assessment in Aortic Stenosis

Because of the aging population, degenerative calcific aortic stenosis is increasing in prevalence, and patients are often of advanced age with substantial comorbidities. Accurate risk assessment is important when discussing potential intervention for valve disease so that patients and families have realistic expectations. The risk of surgery, however, is often overestimated in elderly patients with valve disease and the absence of other significant comorbidities.[19] For example, an 80-year-old man with severe aortic stenosis undergoing a first-time aortic valve replacement with no other cardiac or systemic illness has an estimated perioperative risk of mortality of 1.3% and risk of combined morbidity/mortality of 11% using the Society of Thoracic Surgeons risk calculator.[20] Concomitant pulmonary disease, a combined operation, or history of prior cardiac surgery, however, markedly increases these risks. Rapid and easy-to-use online calculators (eg, www.sts.org) should be used for a starting point in discussions with patients, although the models may overlook other important variables, such as general frailty and disability in the elderly.[21]

Transcatheter Aortic Valve Replacement

The importance of careful risk assessment is further heightened by the emergence of the transcatheter aortic valve replacement (TAVR) procedure, which involves the insertion of an expandable bioprosthetic aortic valve within a stenotic aortic valve. This new procedure has gained Food and Drug Administration approval within the confines of a controlled registry at participating medical centers in operable patients. Supporting data are from the placement of aortic transcatheter valve (PARTNER) trial, which showed that the Edwards SAPIEN aortic valve resulted in improved survival and quality of life compared with standard medical therapy in severe symptomatic aortic stenosis.[22] This new therapy offers an option for the management of aortic stenosis in patients otherwise deemed high risk for traditional aortic valve replacement surgery. Currently, however, the durability of these percutaneous valves remains unknown, and the highly effective option of surgical valve replacement remains the standard of care. Intervention with TAVR earlier in the course of the disease should be avoided, given that the prognosis of asymptomatic aortic stenosis is good and that the percutaneous approach is still associated with substantial risk (stroke occurred in 5% in the PARTNER trial).[22]

MITRAL REGURGITATION

Causes

The management approach to mitral regurgitation is highly dependent on the classification of the specific valvular lesion as either organic (ie, the lesion affects the valve leaflets themselves) or functional (ie, the valve is incompetent due to structural remodeling of the LV). Also important for management, the cause should be classified as acute or chronic. The LV compensates well for long-standing, gradually progressive mitral regurgitation but quickly decompensated with acute severe regurgitation. The most common causes of mitral regurgitation are listed in **Table 3**.

Mitral Valve Prolapse

Mitral valve prolapse is a degenerative connective tissue disease of the mitral valve leaflets characterized by leaflet thickening and redundancy, with a prevalence of 2% to 3% in the population. Mitral valve prolapse is most frequently confirmed by echocardiography, either after the auscultation of a systolic murmur or as an incidental finding (see **Table 1**).[23] Redundancy of the leaflets most frequently leads to failure of coaptation with consequent mitral regurgitation. Dyspnea only develops when mitral regurgitation becomes severe; the constellation of chest pain and palpitations, previously known as a syndrome associated with mitral valve prolapse, is no longer considered a true clinical entity based on more subsequent prospective investigation.[24]

Complications of Mitral Valve Prolapse

The primary complications associated with mitral valve prolapse are

- Gradual worsening of regurgitation, typically over years
- Atrial fibrillation
- Spontaneous chordal rupture, with resultant acute severe regurgitation
- Infective endocarditis

The development of chronic severe mitral regurgitation typically is well tolerated initially, because the ventricle compensates for the volume overload state by dilation with preservation of cardiac output. There is a 7% to 10% per year incidence, however, of patients developing symptoms or cardiac decompensation requiring surgery.[25,26]

Table 3
Common causes of mitral regurgitation

Chronic Organic Mitral Regurgitation	**Chronic Functional Mitral Regurgitation**
Mitral valve prolapse	Dilated cardiomyopathy (either ischemic or nonischemic)
Rheumatic mitral disease	Posterior wall myocardial infarction
Endocarditis (chronic sequela)	Hypertrophic obstructive cardiomyopathy with systolic anterior motion of the mitral valve leaflets
Cleft mitral valve leaflet	
Acute Organic Mitral Regurgitation	**Acute Functional Mitral Regurgitation**
Mitral valve chordal rupture	Acute LV dilation from any cause
Acute infective endocarditis	Acute ischemia, particularly of the posterior wall and/or papillary muscles
	Papillary muscle rupture from acute infarction

Patients with mitral valve prolapse also have a risk of up to 8% of developing spontaneous rupture of the mitral valve chords, which may lead to acute or subacute severe regurgitation.[27] Because acute regurgitation is tolerated poorly, patients may present with pronounced dyspnea and congestive failure. A murmur may not be audible, due to the rapid equalization of pressure between the LV and left atrium, and echocardiography may be necessary to establish the diagnosis. Lastly, mitral valve prolapse is the most common underlying cause of infective endocarditis in developed countries and should always be considered in patients with mitral valve prolapse presenting with nonspecific systemic symptoms, even though the per-patient risk is not excessive.[28,29]

Functional Mitral Regurgitation

The mitral valve is integrated anatomically into the LV, with a network of chordal attachments inserting into a pair of papillary muscles that then insert into the LV myocardium. If the LV chamber becomes dilated (eg, dilated cardiomyopathy) or the posterior wall of the ventricle (where the papillary muscles attach) is dysfunctional (eg, posterior wall myocardial infarction), the mitral valve leaflets are restricted from fully closing during systole and regurgitation occurs.

Grading Mitral Valve Regurgitation Severity

The grading of mitral valve regurgitation is primarily determined with echocardiography. In routine clinical practice, the most commonly used technique relies on the ability of Doppler echocardiography to encode the regional velocity of blood flow using color flow Doppler imaging. The interpreter of the echocardiogram judges approximately what percentage of the left atrial volume is filled with regurgitant blood flow, and a grading scheme is used to determine the severity (**Fig. 2**). Although this technique is practical and clinically useful, limitations include variable machine settings that have an impact on the apparent size of the regurgitant jet and the qualitative determination that depends on the experience and expertise of the interpreter. Other echocardiographic techniques are available for the quantitative determination of regurgitant volume but also suffer from geometric assumptions and substantial interobservor variability.[30] Therefore, an integrative approach to interpretation should be

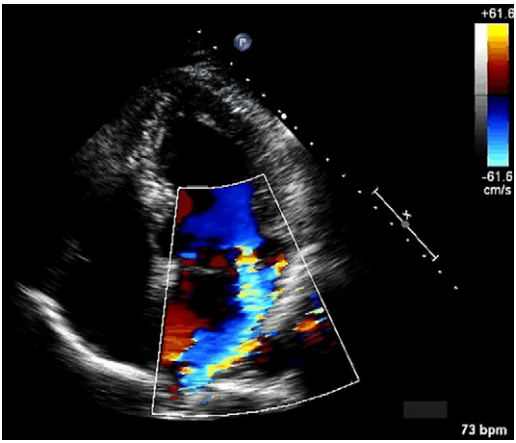

Fig. 2. Transthoracic echocardiographic image shows the color Doppler envelope of mitral regurgitation due to mitral valve prolapse. This type of eccentric Doppler jet along the left atrial wall may be underestimated qualitatively but represents severe regurgitation in this case.

used, including all available techniques when appropriate. Transesophageal echocardiography also may be helpful in more clearly defining the mitral valve anatomy and regurgitation severity.

As with the case of aortic stenosis, because of the inherent limitations and subjectivity of echocardiography, clinical correlation is always important in making management decisions. For example, a patient with mitral valve prolapse who is asymptomatic with normal LV size and function should display unequivocal severe mitral regurgitation before consideration of surgical intervention. In contrast, a symptomatic patient with reportedly moderate mitral regurgitation may warrant further testing with an exercise Doppler echocardiogram or a transesophageal echocardiogram to verify that the regurgitation is not underestimated. Exercise stress testing can also be useful in reportedly asymptomatic patients to confirm adequate functional capacity.[1] In addition, Doppler echocardiography immediately postexercise occasionally reveals more substantial regurgitation that is exercise induced and may explain the symptomatology.

Clinical Follow-up

Gradual progression of mitral regurgitation may eventually lead to severe symptomatic mitral regurgitation and cardiac decompensation. With routine clinical follow-up (**Table 4**), however, progression to severe disease generally is readily detectable, either from symptom development (dyspnea or exercise intolerance) or from structural remodeling by echocardiography.[1] Referral to a cardiologist is appropriate for moderate or severe regurgitation, although the primary care physician maintains a critical role in monitoring for symptoms.

Management of Organic Mitral Valve Regurgitation

Medical therapy with a vasodilator has not been shown beneficial in the treatment of mitral regurgitation, except for the treatment of concomitant hypertension or for stabilization in the setting of acute severe mitral regurgitation.[1] The primary focus is to determine the timing and type of surgery to be performed. As opposed to most other forms of valve disease, severe mitral regurgitation resulting from mitral valve prolapse frequently can be treated with surgical repair rather than valve replacement. Because the long-term outcomes of valve repair are believed superior to replacement, the timing of surgery is influenced by whether repair is believed feasible. The major (class I) recommendations for mitral valve surgery are as follows[1]:

- Symptomatic severe regurgitation (in the absence of severe LV dysfunction)
- Severe regurgitation with mild or moderate LV dysfunction (ejection fraction $\leq$60%) or with an end-systolic LV dimension $\geq$40 mm
- In either of the above indications, mitral valve repair is recommended over replacement with referral to a center experienced in mitral valve repair.

Table 4
Recommended follow-up for chronic mitral regurgitation

Severity	Recommended Follow-up[1,13]
Mild	Clinical evaluation and echocardiogram every 3 y
Moderate	Annual clinic evaluation and echocardiogram
Severe	Annual clinic evaluation and echocardiogram; increase to every 6 mo if serial increase in LV chamber size

Class IIA (benefit likely, with less level of evidence) recommendations also include pulmonary hypertension or new-onset atrial fibrillation in the presence of severe mitral regurgitation as well as severe asymptomatic mitral regurgitation if successful mitral valve repair is probable. The latter indication is one of few in which asymptomatic valve disease, even without evidence of cardiac decompensation, is deemed enough to warrant surgical intervention. Nonetheless, intervention on asymptomatic severe mitral regurgitation, without evidence of cardiac decompensation, remains controversial, both because of subjectivity in the assessment of severity and because some prospective data support a favorable outcome without early intervention.[25] The watchful waiting approach is a reasonable alternative to early mitral valve surgery, particularly in patients with equivocally severe regurgitation, lack of access to a mitral valve repair expert (only few centers perform a high volume of this surgery), or higher surgical risk. These patients require close follow-up, however, with echocardiography at least every 12 months and at intervals of 3 to 6 months if there is evidence of significant chamber enlargement. In addition, patients should be educated about symptom development in mitral regurgitation. Once a class I indication for surgery is present, delayed intervention is associated with a worse outcome in terms of the development of heart failure and death.[31,32]

Evidence of early structural remodeling may also help in making a definitive recommendation for surgery when symptoms are not present—for example, evidence of progressive LV dilation on serial echocardiography that does not yet reach a class I indication or an elevated brain natriuretic peptide.[33] Although mitral valve repair performed by an expert surgeon should be expected to result in a durable valve with essentially normal function, complications can arise, including a suboptimal repair necessitating valve replacement, residual significant regurgitation, functional stenosis, hemolytic anemia, and death (with an operative mortality rate of 1.2%).[34]

Management of Functional Mitral Valve Regurgitation

Because the mechanism of mitral regurgitation in the presence of significant cardiomyopathy involves unfavorable geometric remodeling of the ventricle rather than inherent dysfunction of the valve leaflets, mitral valve surgery does not treat the underlying cause of the regurgitation. Intuitively, correction of mitral valve regurgitation seems to have a positive influence on the cardiomyopathy, and some retrospective or nonrandomized studies have shown a potential benefit for mitral valve repair[35–37] whereas other retrospective analysis showed no benefit.[38] Alternatively, medical therapy for the cardiomyopathy as well as biventricular pacing when a left bundle branch block is present (QRS >130 ms) also is shown to substantially improve the severity of functional mitral regurgitation.[39–42] No randomized study has compared mitral valve repair for functional regurgitation in dilated cardiomyopathy with optimal medical therapy; current ACC/AHA guidelines suggest an individualized approach in this scenario, with a class IIB recommendation for mitral valve surgery and only in the setting of refractory functional class III–IV symptoms despite optimal medical therapy for heart failure.[1] Current guidelines support concomitant mitral valve repair at the time of coronary artery bypass surgery if there is moderate or severe ischemic mitral regurgitation.[1]

OTHER VALVE DISEASE

Aortic Regurgitation

Aortic regurgitation in general can be divided into 2 underlying causes: those that involve the root of the aorta and lead to failure of coaptation of the aortic valve leaflets

(eg, Marfan syndrome with aortic root dilation) and those that involve the leaflets themselves. Leaflet abnormalities can be due to an inflammatory process (eg, rheumatic heart disease) or anatomic abnormalities (eg, bicuspid aortic valve or sequelae of infective endocarditis). In addition, atherosclerotic calcification of the aortic valve that results in aortic stenosis also can cause regurgitation, albeit usually mild regurgitation. Aortic regurgitation typically is identified by a diastolic murmur, symptoms (primarily palpitations, due to the large volume of blood ejected during each contraction, or dyspnea), or as an incidental finding on echocardiography. Significant aortic regurgitation results profound volume overload of the LV, with resulting progressive dilation. In chronic regurgitation, the LV has a remarkable capability to dilate and increase its forward stroke volume, thereby compensating for the backward regurgitant flow. As a result, patients with even severe chronic regurgitation typically remain asymptomatic for years and experience no long-term cardiac sequelae despite moderate amounts of dilation. Chronic severe aortic regurgitation with marked LV chamber dilation eventually results, however, in the development of symptoms and/or LV systolic dysfunction; if this occurs, surgical intervention should proceed without delay to avoid irreversible cardiomyopathy.[1] Echocardiography is an indispensable resource for the identification of aortic regurgitation, allowing assessment of regurgitation severity and measurement of LV dimensions and ejection fraction. As with other valve lesions, the echocardiographic interpretation of regurgitation severity should be taken in context of a patient's clinical presentation and concomitant LV dilation. Cardiac MRI may have an increasing role in the future in the quantification of aortic regurgitation, because mounting evidence has shown an improved discriminatory capability for the assessment of both regurgitant volume and end-systolic volume.[43]

Mitral Stenosis

The prevalence of mitral stenosis has markedly diminished as rheumatic heart disease has become uncommon in the US population, along with that of other developed countries. Rheumatic heart disease still is responsible for the majority of patients presenting with mitral stenosis, although calcific/degenerative mitral stenosis has become more common in the aging population. In rheumatic heart disease, thickening and immobility of the mitral leaflets initially occurs along the commissural edges, with retained mobility in the remainder of the leaflets. The inflammatory process later progresses to involve more of the leaflets and the subvalvular apparatus, with the development of a diastolic pressure gradient between the left atrium and LV. In contrast, calcific/degenerative mitral stenosis results primarily from calcification at the mitral annulus with potentially progressive involvement of the leaflets themselves; the calcification can become sufficiently bulky to impede blood flow into the LV and create a substantial pressure gradient. Lastly, radiation therapy can cause stiffening and fibrosis of the mitral valve leaflets. Typically, the entire anterior leaflet becomes fibrotic and immobile, along with concomitant involvement of the aortic valve that is in the same radiation plane. Dyspnea is the most common presentation of mitral stenosis, although hemoptysis also can occasionally occur. Clinical decision making is based on the severity of symptoms, the severity of the pressure gradient across the mitral valve, and anatomic features of the mitral valve from echocardiography. Assessment of mitral gradients using cardiac catheterization requires assumptions regarding the pressure of the left atrium based on the pulmonary capillary wedge pressure or interatrial septal puncture for direct assessment. In cases of rheumatic mitral stenosis, balloon valvuloplasty is sometimes a therapeutic option that allows surgical intervention to be delayed several years. Predicting the success of balloon valvuloplasty is based on echocardiographic assessment of the anatomy of the affected mitral valve.

Pulmonic Valve Disease

Limiting pulmonic valve disease is uncommon. Pulmonic stenosis is most often caused by a congenital defect, and obstruction typically improves gradually as a child grows, as opposed to a bicuspid aortic valve, which tends to become more restricted in adulthood. Pulmonic regurgitation is most commonly related to pulmonary hypertension and may be both a clue on physical examination (early diastolic murmur at the upper sternal border, similar to aortic regurgitation) and on echocardiography to the presence of pulmonary hypertension. Pulmonic regurgitation may also be a sequela of previously corrected congenital heart disease or, rarely, due to infective endocarditis.

Tricuspid Valve Disease

Tricuspid stenosis is rare and usually due to rheumatic heart disease, in which case concomitant mitral stenosis is invariably also present. The causes of tricuspid regurgitation are analogous to those of mitral regurgitation, in that both cardiomyopathy of the right ventricle or intrinsic tricuspid valve leaflet disease can lead to significant regurgitation (**Table 5**). The most common indication for tricuspid valve surgery is at least moderate tricuspid regurgitation when cardiac surgery is performed for another reason. At least moderate tricuspid regurgitation is present in a substantial proportion of patients with severe mitral regurgitation due to mitral valve prolapse, and outcomes are better if the tricuspid valve is also repaired at the time of mitral surgery.[1] The indications for primary surgery for tricuspid valve disease are not as well validated as for left-sided valve lesions, and the decision is complicated by a prosthetic tricuspid valve that is at higher risk of thromboembolic complications. Symptoms, such as dyspnea and right-sided heart failure, that are clearly attributable to tricuspid valve regurgitation are the most well-defined surgical indication.

INFECTIVE ENDOCARDITIS

Prophylaxis

The AHA guidelines for prophylaxis against infective endocarditis in patients with predisposing cardiac lesions changed substantially in 2007.[44] These new guidelines no longer support prophylactic antibiotics in the majority of patients with valvular heart disease, reserving prophylaxis for patients with only the "highest risk of adverse outcome from infective endocarditis." The decision to change these guidelines was

Table 5
Common causes of tricuspid regurgitation

Chronic Organic Tricuspid Regurgitation	Chronic Functional Tricuspid Regurgitation
Tricuspid valve prolapse	Dilated cardiomyopathy (either ischemic or nonischemic)
Rheumatic tricuspid disease	Pulmonary hypertension
Endocarditis (chronic sequela)	
Carcinoid syndrome	
Injury from pacemaker lead implantation or cardiac biopsy	
Acute Organic Tricuspid Regurgitation	**Acute Functional Tricuspid Regurgitation**
Acute infective endocarditis	Acute right ventricular dilation from any cause

made based not on new evidence but recognition that (1) endocarditis on a per-patient basis is a rare event, (2) the majority of endocarditis cases result from daily exposure to transient bacteremia rather than from dental procedures, and (3) no randomized controlled study has been performed to test the benefit of prophylactic antibiotics. Unfortunately, a randomized controlled study of prophylactic antibiotics will never be practical because of the rarity of endocarditis on a per-patient basis. The current guidelines support prophylaxis for only the conditions listed in **Box 1**.

The new guidelines have caused some controversy regarding the implications for individual patients at risk. Because even patients without the conditions listed in **Box 1** have a high chance of morbidity and an average mortality rate of more than 20% associated with infective endocarditis, the consequences of endocarditis are great.[45] In addition, patients with predisposing cardiac lesions, as a whole, experience a substantial risk of developing endocarditis, as demonstrated by mitral valve prolapse, the most common predisposing lesion for endocarditis.[28] Furthermore, although the overall benefit of prophylaxis on a population level might be small, there is evidence in animal models that antibiotics decrease bacteremia and lower the incidence of infective endocarditis in experimental animal models.[46,47] In a case-control study performed in the Netherlands, among 438 cases of endocarditis, prophylaxis was associated with an estimated 49% efficacy at preventing endocarditis.[48] The risk of antibiotics for prophylaxis seems negligible, because there has never been a reported case of death from antibiotic-associated anaphylaxis for this condition.[44] Therefore, although the population benefit may be small, the authors' opinion is that a risk-benefit discussion should take place between physicians and individuals with predisposing cardiac lesions (eg, mitral valve prolapse with regurgitation or bicuspid aortic valve), and autonomous patients should make their own decision as to whether to take prophylactic antibiotics.[49]

Presentation and Diagnosis

The most important principle in the diagnosis of infective endocarditis is the initial consideration of the diagnosis in any patient with an unexplained fever for greater than 48 hours. Subacute endocarditis often presents with nonspecific symptoms and signs, such as chronic fevers and weight loss, that require a high degree of suspicion. Although auscultation of a murmur in this scenario should increase suspicion for the diagnosis, serial blood cultures (at least 2) are necessary in any patient with persistent fevers without a clear cause, even in the absence of a murmur (ACC/AHA class I indication).[1] The sensitivity of serial blood cultures for the diagnosis of infective

Box 1
AHA 2007 guidelines—conditions requiring antibiotic prophylaxis for dental procedures

- Prosthetic cardiac valves or material used for valve repair
- Previous endocarditis
- Congenital heart disease only for the following conditions
  - Uncorrected cyanotic congenital defect
  - Repaired congenital defect with prosthetic material for the first 6 months postprocedure
  - Repaired congenital defect with residual shunt at the site of repair with prosthetic material, indefinitely
- Cardiac transplant with valvulopathy

endocarditis is 97%.[50] Furthermore, because of the importance of blood cultures in the diagnosis, antibiotics should not be initiated until after at least 2 sets of blood cultures have been drawn, because the most common cause of negative cultures is prior antibiotic use.[1] The modified Duke criteria, which rely on a combination of blood culture testing, echocardiography, and physical examination signs, establish the probability of a true diagnosis of endocarditis with good sensitivity and specificity in most cases.[1,50] Transthoracic echocardiography is recommended to investigate for the presence of endocarditis in patients with persistent bacteremia (>4 days' treatment of bacteremia) or to help identify the less common culture-negative endocarditis in patients with fever of unknown origin or other presentations compatible with endocarditis. Transthoracic echocardiography, with a sensitivity of 60% to 75%, is generally a good first-line approach, although patients with prosthetic valves generally should be evaluated with transesophageal echocardiography, with its higher sensitivity of 95%.[51] Transesophageal echocardiography should be obtained for suspected native valve endocarditis when the transthoracic study is nondiagnostic or if it is negative when the pretest probability is significant.

Treatment

After diagnosis of endocarditis is established, intravenous antibiotics should be initiated and continued for 4 to 6 weeks, per guideline recommendations.[1] Surgery for native valve endocarditis is indicated (class I) for valve stenosis or regurgitation causing heart failure; for severe aortic regurgitation or mitral regurgitation with elevated LV end-diastolic or left atrial pressures; for fungal endocarditis or other highly resistant organisms; or for complications of heart block, abscess, or destructive penetrating lesions (see ACC/AHA valve disease guidelines for details).[1] Additional indications for surgery include recurrent embolic phenomena or progressive vegetation growth despite appropriate antibiotics (class IIa) and mobile vegetation size greater than 10 mm (class IIb). A recent randomized prospective study of early surgery (within 48 hours of randomization) among patients with left-sided infective endocarditis and severe valve disease with large vegetations showed a reduction from 28% to 3% for a composite endpoint that was primarily driven by embolic events.[52] This important finding may influence future guidelines and warrants consideration in the decision making for surgery.

SUMMARY

Heart valve disease is commonly encountered in clinical practice. Primary care physicians have an important role in the initial decision to pursue echocardiography and/or cardiac referral in patients found to have murmurs and in continued follow-up for change in clinical status. A common theme for all valve disease is the need for appropriate follow-up and testing to determine the ideal timing for surgical intervention, attempting to avoid valve surgery before it is necessary yet refer for intervention before the onset of advanced and potentially irreversible cardiac remodeling and clinical decompensation. In any form of valve disease, symptoms (primarily dyspnea) remain the clearest indication for surgery, and the primary care physician maintains a critical role in both patient education and serial evaluation for these symptoms.

REFERENCES

1. American College of Cardiology/American Heart Association Task Force on Practice Guidelines, Society of Cardiovascular Anesthesiologists, Society for Cardiovascular Angiography and Interventions, Society of Thoracic Surgeons,

Bonow RO, Carabello BA, Kanu C, et al. ACC/AHA 2006 guidelines for the management of patients with valvular heart disease: a report of the American College of Cardiology/American Heart Association Task Force on Practice Guidelines (writing committee to revise the 1998 Guidelines for the Management of Patients With Valvular Heart Disease): developed in collaboration with the Society of Cardiovascular Anesthesiologists: endorsed by the Society for Cardiovascular Angiography and Interventions and the Society of Thoracic Surgeons. Circulation 2006;114(5):e84–231.
2. Cripe L, Andelfinger G, Martin LJ, et al. Bicuspid aortic valve is heritable. J Am Coll Cardiol 2004;44(1):138–43.
3. Stewart BF, Siscovick D, Lind BK, et al. Clinical factors associated with calcific aortic valve disease. Cardiovascular health study. J Am Coll Cardiol 1997; 29(3):630–4.
4. Otto CM, Pearlman AS, Gardner CL. Hemodynamic progression of aortic stenosis in adults assessed by Doppler echocardiography. J Am Coll Cardiol 1989;13(3): 545–50.
5. Davies SW, Gershlick AH, Balcon R. Progression of valvar aortic stenosis: a long-term retrospective study. Eur Heart J 1991;12(1):10–4.
6. Roger VL, Tajik AJ, Bailey KR, et al. Progression of aortic stenosis in adults: new appraisal using Doppler echocardiography. Am Heart J 1990;119(2 Pt 1):331–8.
7. Rosenhek R, Binder T, Porenta G, et al. Predictors of outcome in severe, asymptomatic aortic stenosis. N Engl J Med 2000;343(9):611–7.
8. Ross J Jr, Braunwald E. Aortic stenosis. Circulation 1968;38(Suppl 1):61–7.
9. Turina J, Hess O, Sepulcri F, et al. Spontaneous course of aortic valve disease. Eur Heart J 1987;8(5):471–83.
10. Kelly TA, Rothbart RM, Cooper CM, et al. Comparison of outcome of asymptomatic to symptomatic patients older than 20 years of age with valvular aortic stenosis. Am J Cardiol 1988;61(1):123–30.
11. Baumgartner H, Hung J, Bermejo J, et al. American Society of E, European Association of E. Echocardiographic assessment of valve stenosis: EAE/ASE recommendations for clinical practice [Erratum appears in J Am Soc Echocardiogr 2009;22(5):442]. J Am Soc Echocardiogr 2009;22(1):1–23 [quiz: 101–2].
12. Rossebo AB, Pedersen TR, Boman K, et al. Intensive lipid lowering with simvastatin and ezetimibe in aortic stenosis. N Engl J Med 2008;359(13):1343–56.
13. American College of Cardiology Foundation Appropriate Use Criteria Task Force, American Society of Echocardiography, American Heart Association, American Society of Nuclear Cardiography, Heart Failure Society of America, Heart Rhythm Society, Society for Cardiovascular Angiography and Interventions, Society of Critical Care Medicine, Society of Cardiovascular Computed Tomography, Society for Cardiovascular Magnetic Resonance, Douglas PS, Garcia MJ, Haines DE, et al. ACCF/ASE/AHA/ASNC/HFSA/HRS/SCAI/SCCM/SCCT/SCMR 2011 Appropriate Use Criteria for Echocardiography. A Report of the American College of Cardiology Foundation Appropriate Use Criteria Task Force, American Society of Echocardiography, American Heart Association, American Society of Nuclear Cardiology, Heart Failure Society of America, Heart Rhythm Society, Society for Cardiovascular Angiography and Interventions, Society of Critical Care Medicine, Society of Cardiovascular Computed Tomography, and Society for Cardiovascular Magnetic Resonance Endorsed by the American College of Chest Physicians. J Am Coll Cardiol 2011;57(9):1126–66.
14. Rosenhek R, Zilberszac R, Schemper M, et al. Natural history of very severe aortic stenosis. Circulation 2010;121(1):151–6.

15. Kang DH, Park SJ, Rim JH, et al. Early surgery versus conventional treatment in asymptomatic very severe aortic stenosis. Circulation 2010;121(13): 1502–9.
16. Amato MC, Moffa PJ, Werner KE, et al. Treatment decision in asymptomatic aortic valve stenosis: role of exercise testing. Heart 2001;86(4):381–6.
17. Das P, Rimington H, Chambers J. Exercise testing to stratify risk in aortic stenosis. Eur Heart J 2005;26(13):1309–13.
18. Vahanian A, Baumgartner H, Bax J, et al. Task force on the management of valvular hearth disease of the European Society of C, Guidelines ESCCfP. Guidelines on the management of valvular heart disease: the task force on the management of valvular heart disease of the European Society of Cardiology. Eur Heart J 2007;28(2):230–68.
19. Varadarajan P, Kapoor N, Bansal RC, et al. Survival in elderly patients with severe aortic stenosis is dramatically improved by aortic valve replacement: results from a cohort of 277 patients aged > or = 80 years. Eur J Cardiothorac Surg 2006; 30(5):722–7.
20. Risk calculator and models. The Society of Thoracic Surgeons. Available at: www.sts.org. Accessed August 8, 2012.
21. Afilalo J, Mottillo S, Eisenberg MJ, et al. Addition of frailty and disability to cardiac surgery risk scores identifies elderly patients at high risk of mortality or major morbidity. Circ Cardiovasc Qual Outcomes 2012;5(2):222–8.
22. Leon MB, Smith CR, Mack M, et al. Transcatheter aortic-valve implantation for aortic stenosis in patients who cannot undergo surgery. N Engl J Med 2010; 363(17):1597–607.
23. Freed LA, Levy D, Levine RA, et al. Prevalence and clinical outcome of mitral-valve prolapse. N Engl J Med 1999;341(1):1–7.
24. Devereux RB, Kramer-Fox R, Brown WT, et al. Relation between clinical features of the mitral prolapse syndrome and echocardiographically documented mitral valve prolapse. J Am Coll Cardiol 1986;8(4):763–72.
25. Rosenhek R, Rader F, Klaar U, et al. Outcome of watchful waiting in asymptomatic severe mitral regurgitation. Circulation 2006;113(18):2238–44.
26. Kang D-H, Kim JH, Rim JH, et al. Comparison of early surgery versus conventional treatment in asymptomatic severe mitral regurgitation. Circulation 2009; 119(6):797–804.
27. Enriquez-Sarano M, Basmadjian AJ, Rossi A, et al. Progression of mitral regurgitation: a prospective Doppler echocardiographic study. J Am Coll Cardiol 1999; 34(4):1137–44.
28. Murdoch DR, Corey GR, Hoen B, et al. International Collaboration on Endocarditis-Prospective Cohort Study I. Clinical presentation, etiology, and outcome of infective endocarditis in the 21st century: the International Collaboration on Endocarditis-Prospective Cohort Study. Arch Intern Med 2009;169(5): 463–73.
29. Clemens JD, Horwitz RI, Jaffe CC, et al. A controlled evaluation of the risk of bacterial endocarditis in persons with mitral-valve prolapse. N Engl J Med 1982;307(13):776–81.
30. Biner S, Rafique A, Rafii F, et al. Reproducibility of proximal isovelocity surface area, vena contracta, and regurgitant jet area for assessment of mitral regurgitation severity. JACC Cardiovasc Imaging 2010;3(3):235–43.
31. Ling LH, Enriquez-Sarano M, Seward JB, et al. Early surgery in patients with mitral regurgitation due to flail leaflets: a long-term outcome study. Circulation 1997;96(6):1819–25.

32. Enriquez-Sarano M, Avierinos JF, Messika-Zeitoun D, et al. Quantitative determinants of the outcome of asymptomatic mitral regurgitation. N Engl J Med 2005; 352(9):875–83.
33. Pizarro R, Bazzino OO, Oberti PF, et al. Prospective validation of the prognostic usefulness of brain natriuretic peptide in asymptomatic patients with chronic severe mitral regurgitation. J Am Coll Cardiol 2009;54(12):1099–106.
34. Gammie JS, Sheng S, Griffith BP, et al. Trends in mitral valve surgery in the United States: results from the Society of Thoracic Surgeons Adult Cardiac Surgery Database. Ann Thorac Surg 2009;87(5):1431–7 [discussion: 1437–9].
35. Bishay ES, McCarthy PM, Cosgrove DM, et al. Mitral valve surgery in patients with severe left ventricular dysfunction. Eur J Cardiothorac Surg 2000;17(3):213–21.
36. Bolling SF, Pagani FD, Deeb GM, et al. Intermediate-term outcome of mitral reconstruction in cardiomyopathy. J Thorac Cardiovasc Surg 1998;115(2):381–6 [discussion: 387–8].
37. Chen FY, Adams DH, Aranki SF, et al. Mitral valve repair in cardiomyopathy. Circulation 1998;98(Suppl 19):II124–7.
38. Wu AH, Aaronson KD, Bolling SF, et al. Impact of mitral valve annuloplasty on mortality risk in patients with mitral regurgitation and left ventricular systolic dysfunction. J Am Coll Cardiol 2005;45(3):381–7.
39. Capomolla S, Febo O, Gnemmi M, et al. Beta-blockade therapy in chronic heart failure: diastolic function and mitral regurgitation improvement by carvedilol. Am Heart J 2000;139(4):596–608.
40. Linde C, Leclercq C, Rex S, et al. Long-term benefits of biventricular pacing in congestive heart failure: results from the MUltisite STimulation in cardiomyopathy (MUSTIC) study. J Am Coll Cardiol 2002;40(1):111–8.
41. Breithardt OA, Sinha AM, Schwammenthal E, et al. Acute effects of cardiac resynchronization therapy on functional mitral regurgitation in advanced systolic heart failure [Erratum appears in J Am Coll Cardiol 2003;41(10):1852]. J Am Coll Cardiol 2003;41(5):765–70.
42. St John Sutton MG, Plappert T, Abraham WT, et al. Multicenter InSync Randomized Clinical Evaluation Study G. Effect of cardiac resynchronization therapy on left ventricular size and function in chronic heart failure. Circulation 2003; 107(15):1985–90.
43. Myerson SG, d'Arcy J, Mohiaddin R, et al. Clinical outcome in Aortic regurgitation with cardiovascular magnetic resonance. Circulation 2012;126(12):1452–60.
44. Wilson W, Taubert KA, Gewitz M, et al, American Heart Association Rheumatic Fever, Endocarditis, and Kawasaki Disease Committee, American Heart Association Council on Cardiovascular Disease in the Young, American Heart Association Council on Clinical Cardiology, American Heart Association Council on Cardiovascular Surgery and Anesthesia, Quality of Care and Outcomes Research Interdisciplinary Working Group. Prevention of infective endocarditis: guidelines from the American Heart Association: a guideline from the American Heart Association Rheumatic Fever, Endocarditis, and Kawasaki Disease Committee, Council on Cardiovascular Disease in the Young, and the Council on Clinical Cardiology, Council on Cardiovascular Surgery and Anesthesia, and the Quality of Care and Outcomes Research Interdisciplinary Working Group [Erratum appears in Circulation 2007;116(15):e376–7]. Circulation 2007;116(15):1736–54.
45. Durante-Mangoni E, Bradley S, Selton-Suty C, et al, International Collaboration on Endocarditis Prospective Cohort Study G. Current features of infective endocarditis in elderly patients: results of the International Collaboration on Endocarditis Prospective Cohort Study. Arch Intern Med 2008;168(19):2095–103.

46. Glauser MP, Francioli P. Successful prophylaxis against experimental streptococcal endocarditis with bacteriostatic antibiotics. J Infect Dis 1982;146(6):806–10.
47. Malinverni R, Overholser CD, Bille J, et al. Antibiotic prophylaxis of experimental endocarditis after dental extractions. Circulation 1988;77(1):182–7.
48. Van der Meer JT, Van Wijk W, Thompson J, et al. Efficacy of antibiotic prophylaxis for prevention of native-valve endocarditis. Lancet 1992;339(8786):135–9.
49. Bach DS. Antibiotic prophylaxis for infective endocarditis: ethical care in the era of revised guidelines. Methodist Debakey Cardiovasc J 2010;6(4):48–52.
50. Li JS, Sexton DJ, Mick N, et al. Proposed modifications to the Duke criteria for the diagnosis of infective endocarditis. Clin Infect Dis 2000;30(4):633–8.
51. Mugge A, Daniel WG, Frank G, et al. Echocardiography in infective endocarditis: reassessment of prognostic implications of vegetation size determined by the transthoracic and the transesophageal approach. J Am Coll Cardiol 1989; 14(3):631–8.
52. Kang DH, Kim YJ, Kim SH, et al. Early surgery versus conventional treatment for infective endocarditis. N Engl J Med 2012;366(26):2466–73.