

HIV-associated cryptococcal meningitis

Joseph N. Jarvis and Thomas S. Harrison

AIDS 2007, **21**:2119–2129

Keywords: clinical presentation, cryptococcal meningitis, *Cryptococcus*, epidemiology, HIV, therapy

Introduction

While the incidence of cryptococcal meningitis in the developed world has declined with widespread, early antiretroviral therapy (ART), cryptococcal disease remains a major opportunistic infection and leading cause of mortality in patients infected with HIV in much of the developing world. Most HIV-related cases are caused by *Cryptococcus neoformans* var. *grubii* (serotype A), while var. *neoformans* (serotype D) is responsible for a proportion, especially in Europe, and there are a small number of *Cryptococcus gattii* infections (formerly *C. neoformans* serotypes B and C) [1,2]. The last includes a small number of cases in HIV-infected individuals forming part of an unprecedented outbreak of *C. gattii* infections, predominantly in apparently immunocompetent patients, on Vancouver Island, Canada [3,4].

C. neoformans is distributed worldwide. An ubiquitous environmental saphrophyte, it is found in soil contaminated with pigeon droppings and has also been isolated from the heartwood of several tree species in South America [5] and India [6], and from the homes of African HIV-seropositive patients [7,8]. Exposure may be common [9], although the exact circumstances are usually unclear. Inhalation of small, thinly encapsulated yeasts, or basidiospores [10], may lead to an initial pulmonary infection, which, depending on host immune response and the number and virulence of the organisms, is cleared, contained within granulomata as a latent infection or disseminates. The minority in whom disease disseminates typically have defects in T cell function, through

malignancy, immunosuppressive medication, autoimmune disease or sarcoidosis [11,12] or HIV infection, indicating the role of T cell-mediated immunity in host defence.

In HIV-seropositive patients, most episodes of cryptococcal meningitis probably represent reactivation of latent infection, which may have been acquired many years earlier. There is compelling evidence for latent infection in a rat model [13] and humans [14]. Dromer and colleagues [15] typed *C. neoformans* isolates from HIV-seropositive patients diagnosed with cryptococcosis in France, some of whom were from Africa but had lived in France for a median of over 9 years. There was a significant clustering of isolates from African compared with European patients, suggesting that the patients had acquired their isolates long before the development of clinical disease. A proportion of HIV-related cases, however, may result from dissemination of new or primary infection [16], as has been observed in the recent outbreak of *C. gattii* infection in British Columbia [17].

HIV-associated cryptococcal meningitis usually presents as a subacute meningo-encephalitis in profoundly immunosuppressed patients (CD4 cell counts < 100 cells/ μ l), with malaise, headache, fever and, later, visual disturbance and altered mental status. Signs, if present, may include meningism, papilloedema, cranial nerve palsies [particularly sixth nerve palsies reflective of raised pressure in cerebrospinal fluid (CSF)] and reduced conscious level. The diagnosis is usually straightforward. The high organism load in this setting means the sensitivity of India ink staining of CSF is high. Those who have a negative

From the Centre for Infection, St George's University of London, London UK.

Correspondence to Dr T.S. Harrison, Centre for Infection, Department of Cellular and Molecular Medicine, St George's University of London, Cranmer Terrace, London SW17 0RE, UK.

E-mail: tharriso@sgul.ac.uk

Received: 10 April 2007; revised: 24 May 2007; accepted: 25 May 2007.

result with India ink can be diagnosed by highly sensitive and specific cryptococcal antigen testing of CSF, or serum if CSF cannot be obtained [18]. Lumbar puncture often reveals markedly elevated opening pressures, an important complicating factor, with only modestly elevated or normal white cell counts (usually lymphocytes), elevated protein and low or normal glucose.

High organism burden at baseline (indicated by quantitative CSF culture or CSF antigen titre) and abnormal mental status are the most important predictors of death [19,20], while high opening pressures and a poor inflammatory response in the CSF have also been associated with poor outcome [19,21,22]. Autopsy series reveal the lack of a protective granulomatous response in HIV-seropositive patients with cryptococcal meningitis. There is extensive involvement of brain parenchyma in addition to meningitis and higher organism burdens (which are predominantly extracellular) compared with the infection in HIV-seronegative individuals [23–25].

The remainder of this review will focus on the current epidemiology and management of HIV-associated cryptococcal meningitis, with some emphasis on the developing world where the burden of disease is highest. In addition to antifungal therapy, the important complications of elevated CSF pressure and immune reconstitution inflammatory syndrome (IRIS) and future approaches to prevention and therapy are discussed.

Epidemiology

Increasing numbers of cases of cryptococcal meningitis were reported in young adults in the former Zaire throughout the 1960s, possibly representing the first signs of the evolving HIV epidemic [26,27]. The late 1970s and early 1980s saw a sharp increase in the numbers of cases both in Kinshasa [28,29] and in Zairian immigrants to Europe [30–32], many of whom had, in retrospect, features suggestive of AIDS [33].

As the HIV epidemic expanded in the 1980s, *C. neoformans* emerged as an important opportunistic infection in the United States, Europe and Australia, occurring in 5–10% of all AIDS patients [34–38]. Rates of infection declined through the 1990s, initially with the widespread and frequent use of azoles to treat candidiasis [38,39], and subsequently with the introduction of HAART [40,41]. The annual incidence in AIDS patients in Atlanta fell from 66 per 1000 in 1992 to 7 per 1000 in 2000 [41].

HIV-related cryptococcal meningitis is now a problem in the West in patients who present with late-stage HIV infection, typically those with limited access to healthcare [40,41]. However, it remains a major opportunistic infection in the developing world in areas of high HIV

seroprevalence [42,43]. *C. neoformans* is the leading cause of meningitis in central and southern Africa, accounting for 26.5% of cases in a series from Malawi [44], 31% in a series from the Central African Republic [45] and 45% from Zimbabwe [46]. In these areas, it is one of the main causes of mortality in cohorts of HIV-infected individuals, responsible for 13–44% of all deaths [47–49]. For comparison, 5–13% of deaths were attributed to tuberculosis in these studies. In Thailand, cryptococcosis accounts for up to 20% of AIDS-defining illnesses [43,50] and it is reported as a major opportunistic infection in India [51] and Brazil [52]. There are interesting geographical variations in incidence that presumably relate to differential rates of exposure. For example, cryptococcal disease appears to be more common in southern and east Africa than in west Africa [53], and in north and northeast Thailand compared with southern Thailand [43].

Even with current optimal treatment, the 10-week mortality of HIV-associated cryptococcal meningitis is high, ranging from 10 to 25% in developed countries, with no evidence of any decrease in recent years [54]. Of note, mortality is higher in less selected series [55] compared with clinical trials in which very sick patients are excluded [21]. In unselected series from resource-poor settings, acute mortality is up to 43% even with amphotericin B therapy [56]. In Zambia, median survival with low-dose fluconazole monotherapy was 19 days [57], barely better than that in the absence of antifungal therapy [57–59]. In South Africa, in a recent unselected prospective series [60], overall 10-week mortality was 37% despite initial treatment with amphotericin B for most patients and access to ART (Fig. 1).

However, this last study also confirmed that, once over the acute cryptococcal infection and established on ART, the long-term outlook is good, as in the developed country setting, with a levelling of the survival curve. Therefore, in the setting of expanding access to ART

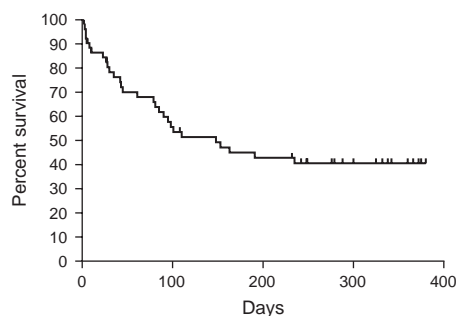


Fig. 1. Prospective observational study of survival of 54 patients with HIV-associated cryptococcal meningitis treated according local protocol (49 with amphotericin B 1 mg/kg daily, 5 with fluconazole) in Cape Town South Africa. Patients not already taking antiretroviral therapy at the time of presentation were started on therapy from 4 weeks after antifungal therapy. (From data in Bicanic *et al.* [60].)

across the developing world, the urgent challenge is to improve acute management and thereby increase the proportion of patients surviving the critical initial months.

Antifungal therapy

Current antifungal treatment guidelines (Table 1; [61,62]) are based in large part on the results of a large, randomized trial published a decade ago [21]. Initial therapy was with amphotericin B (0.7 mg/kg daily) with or without flucytosine (100 mg/kg daily) for 2 weeks, followed by an 8-week consolidation phase with either fluconazole (400 mg daily) or itraconazole (400 mg daily). The rationale was to gain control of infection with initial more rapidly active amphotericin B-based therapy but switch to well-tolerated azoles for consolidation treatment to minimize the dose-dependent toxicity of amphotericin B. The mortality was the lowest of any published trial, at 9.4% in the first 10 weeks. The addition of flucytosine was associated with a trend towards a higher proportion of patients with sterile CSF at 2 weeks and reduced relapse. Fluconazole was superior to itraconazole for consolidation treatment [21]. That the combination of amphotericin B plus flucytosine is more rapidly fungicidal than amphotericin B alone has been demonstrated in a subsequent study in Thailand using serial quantitative cultures to assess the rate of clearance of cryptococcal colony-forming units from the CSF or early fungicidal activity. The clearance of cryptococci from CSF was significantly faster with amphotericin B plus flucytosine than with amphotericin B alone, amphotericin B plus fluconazole (at 400 mg daily) or a combination of all three (Fig. 2 [20]).

Both these studies also demonstrated that, with appropriate monitoring, conventional amphotericin B is reasonably well tolerated, with drug discontinuations in 3% of patients in the first 2 weeks in the Mycoses Study Group trial [21]. Saline and fluid loading equivalent to 1 litre normal saline

daily should be given unless contraindicated, to minimize nephrotoxicity [63], and electrolytes replaced as required. Anaemia, secondary to suppression of erythropoietin transcription [64], is also a predictable side effect of amphotericin B [65–67]. This may be more clinically significant in populations with lower baseline haemoglobin levels, and where transfusion, when occasionally needed, is difficult.

Flucytosine, at the historically low daily dose of 100 mg/kg, was also well tolerated without real-time drug level monitoring in either trial. A substudy of the Thai trial comparing oral and intravenous flucytosine at the same daily dosage of 100 mg/kg has provided some insight into this observation. In contrast to earlier studies in other patient populations, oral bioavailability of flucytosine in these patients at a late stage of HIV infection was only around 50%, resulting in relatively low serum concentration, of an order not usually associated with toxicity. Nevertheless, despite the lower serum levels, patients on oral formulation had the same rate of clearance of infection as those on intravenous formulation [68], consistent with evidence for the dose-independent activity of flucytosine [69–71]. The data suggest that even 100 mg/kg daily, if given intravenously, may be in excess of that required for maximal additional fungicidal activity.

If renal impairment does develop, liposomal amphotericin B, at 3 mg/kg daily, provides a less nephrotoxic and equally effective alternative. A small study suggested liposomal amphotericin B, at 4 mg/kg daily, was more active than conventional amphotericin B [72], but a larger study found no difference in the proportion of patients with sterile CSF at 2 weeks in patients receiving daily liposomal amphotericin B at 3 or 6 mg/kg compared with conventional amphotericin B at 0.7 mg/kg daily [73].

Unfortunately, in many resource-poor settings, amphotericin B is not available or cannot be used safely because of lack of monitoring, and fluconazole, widely available, through a free access programme or in generic form, is the only treatment option. Outcomes with initial

Table 1. Antifungal treatment recommendations for HIV-associated cryptococcal meningitis^a.

	Preferred daily regimen [61,62]	Notes
First 2 weeks	Amphotericin B (AmB) 0.7–1 mg/kg <i>plus</i> flucytosine 100 mg/kg ^b	If flucytosine not tolerated or not available, consider AmB at 1 mg/kg daily If AmB not tolerated, consider liposomal AmB at 3 mg/kg daily if available; if not, switch early to fluconazole at 800 mg daily
Next 8 weeks	Fluconazole 400 mg ^c	If no facility for i.v. therapy, consider fluconazole at \geq 800 mg daily
Thereafter, until immune-reconstitution (see text)	Fluconazole 200 mg	

Am B, amphotericin B; i.v., intravenous.

^aAdapted from Bicanic, 2005 (Bicanic T, Harrison TS. Cryptococcal meningitis. *Br Med Bull* 2005; **72**: 99–118).

^bAdjust for renal impairment; oral or i.v. formulation; if i.v. formulation, consider 75 mg/kg daily [68].

^cAdjust for renal impairment; increase dose by 50% if concomitant rifampicin.

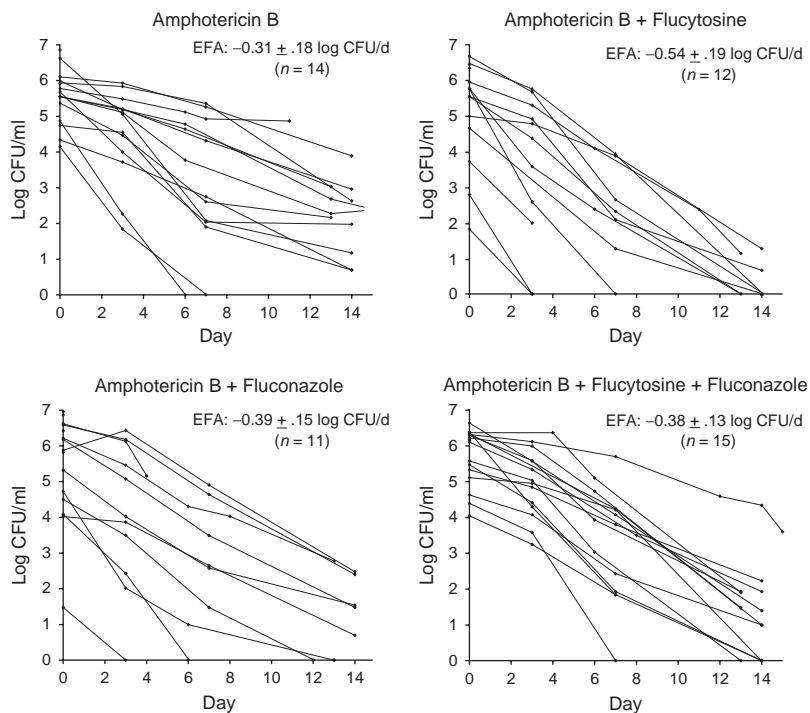


Fig. 2. Fall in *Cryptococcus neoformans* colony-forming units (CFU) in cerebrospinal fluid (CSF) over time by treatment group. The decrease in log CFU/ml CSF per day was calculated for each patient using the slope of the linear regression of log CFU against time. For each treatment group, early fungicidal activity (EFA) is shown as the mean (\pm SD) rate of fall in log CFU. EFA was significantly greater for amphotericin B (AmB) plus flucytosine compared with AmB alone ($P < 0.001$), AmB plus fluconazole ($P = 0.02$), or triple therapy with AmB, flucytosine and fluconazole ($P = 0.02$). (Adapted from Brouwer *et al.* [20], with permission).

fluconazole monotherapy at 200–400 mg daily have not been good, either in early US-based studies [19,74], including a small randomized study in which 400 mg daily was clinically inferior to amphotericin B plus flucytosine [74], or in more recent series from Africa [57,75,76]. Although the earlier randomized study comparing amphotericin B with fluconazole found no significant difference in clinical outcomes, time to sterilization was very long for fluconazole (median 64 days), and outcomes for both drugs were poor [19]. Furthermore, the dosages used for both drugs were lower than currently recommended, making interpretation difficult. The 10-week mortality of approximately 50% with initial fluconazole monotherapy reported by Schaars and colleagues [75] in South Africa represents a minimum estimate in this setting given the retrospective nature of the study with incomplete out-patient follow up. Recent work from Cape Town has demonstrated that 400 mg fluconazole daily is essentially fungistatic over the first 2 weeks of treatment [60]. The resulting prolonged period with a high viable organism load may predispose to the development of fluconazole resistance. Such resistance is a significant problem when initial therapy is with fluconazole [77]. A further concern is that prolonged active infection could also increase the risk of immune reconstitution reactions (see below) following introduction of ART, although data on this point are lacking.

Animal studies suggest a dose–response relationship with increasing fluconazole levels [78]. There is a linear plasma concentration–dose relationship with fluconazole at up to 2 g daily [79], and doses up to 1600 mg daily have appeared safe in small numbers of patients [79,80]. In addition there is a suggestion of a dose–response relationship in terms of the time to sterilization of CSF: with a median time to CSF sterilization of 64 days with 200–400 mg daily [19], a mean time of 41 days with 400 mg daily [74], and 21 [81] and 33 days [82] with 800 mg daily. On this basis, and given the unsatisfactory results of treatment at lower doses, a dose-escalation study of fluconazole therapy is currently underway in Uganda. In the meantime, in settings where amphotericin B cannot be used safely and fluconazole is the only option, the authors would suggest a starting dose of at least 800 mg daily (Table 1).

The combination of fluconazole plus flucytosine is additive or synergistic in murine models [83,84], although not in a study in rabbits [78]. A clinical study in Uganda suggested benefit with addition of flucytosine to fluconazole, although the dose of fluconazole was low (200 mg daily) [76]; and in a small series from the United States, the combination of flucytosine and fluconazole at 400 mg daily resulted in a relatively short median time to sterilization of CSF of 23 days, although side effects with the combination appeared frequent [85]. Further comparative trials to examine the fungicidal activity

and toxicity of this combination with higher doses of fluconazole are warranted in settings where intravenous amphotericin B-based therapy is not possible.

While not as effective, at conventional dosages, as amphotericin B for initial therapy, fluconazole is highly effective and safe as maintenance therapy [86–88]. Increasing evidence suggests discontinuation of this secondary prophylaxis is safe if there has been a significant and sustained immune reconstitution with ART (CD4 cell count > 200 cells/ μ l for > 6 months) [89–91].

Raised cerebrospinal fluid opening pressure

Significantly raised intracranial pressure is a major problem in cryptococcal meningitis, with over half of patients having pressures > 25 cmH₂O and nearly a third pressures > 35 cmH₂O in an analysis of the last Mycosis Study Group Trial [22]. Raised CSF pressure was associated with cognitive impairment, more cranial nerve lesions and increased short-term mortality. Prolonged raised CSF pressure usually manifests as severe headache, papilloedema, and progressive loss of vision, hearing impairment and decreased level of consciousness [92]. The mechanisms leading to increased pressure are debated [22,93,94]. Although a marked inflammatory response is not a feature of HIV-associated cryptococcal meningitis, it is possible cerebral oedema plays a role in some patients. Vascular endothelial growth factor, a mediator of vascular permeability, has been measured in the CSF of patients with cryptococcal disease [95,96], although no correlation between levels of this growth factor and CSF opening pressure has been demonstrated. Instead, the primary deficit is likely to be blockage of CSF reabsorption at the arachnoid villi because of the presence of organisms and shed polysaccharide [23–25]. This would be consistent with the association of raised pressure with higher CSF antigen titre and higher rates of India ink positivity [22], and it would explain why ventricular size usually remains normal, as there is no pressure gradient between the ventricles and the CSF over the convexities of the brain.

In terms of management, few controlled trials have been carried out, so recommendations are based on small series and expert opinion. Current US guidelines suggest daily lumbar punctures for all patients with elevated baseline opening pressures (> 25 cmH₂O), with the removal of sufficient CSF to reduce pressures by 50%, continued until pressure has been normal for several days [61]. The maximum volume of CSF that is safe to remove at a single lumbar puncture is unclear but 20–30 ml is probably reasonable [97]. If facilities allow, computed tomographic or magnetic resonance scanning of the head should be done prior to initial lumbar puncture or if suspected raised CSF pressure develops on therapy in order to exclude rare cases

of true hydrocephalus and space-occupying lesions. In the rare cases in which hydrocephalus develops, a ventriculo-peritoneal shunt should be inserted [98]. When repeated lumbar punctures fail to control pressure and the patient's condition is deteriorating, CSF drainage can be achieved with a ventricular or, less invasive, lumbar drain [99,100]. It is unclear how long the defect in CSF reabsorption persists, but it may be that a significant proportion of patients will respond to relatively short-term drainage with a temporary system [99]. These allow the continual, controlled drainage of high volumes of fluid (approximately 200 ml daily) to a set pressure level, are relatively straightforward to insert, and have a low risk of complications with adequate monitoring and nursing and medical staff who are familiar with their use [101,102].

The use of mannitol, acetazolamide, and corticosteroids for raised CSF pressure is not supported by available evidence [61]. A randomized trial of acetazolamide was terminated early [103]; and high-dose steroids were associated with higher mortality in patients with elevated CSF pressures in a large, although uncontrolled, study [22].

Cryptococcal meningitis immune reconstitution syndrome

As has been described with other opportunistic infections [104–106], initiation of ART can lead to restoration of immune responses to viable or killed organisms or shed antigen; this, in turn, can lead to a paradoxical clinical deterioration; with the uncovering of previously sub-clinical cryptococcal disease or relapse of previously treated infection. Cryptococcal IRIS has been reported in 6–30% of patients with cryptococcal meningitis following commencement of ART [107,108] and may be fatal [108,109]. In the US study, the median time to onset of symptoms after starting ART was 30 days [107]; however, cases have been reported after many months [108]. Presentations include mediastinal lymphadenitis [110], abscesses [111,112] and cavitary pneumonia [113], with the commonest being recurrence of meningitis [107–109]. Cases of IRIS have been characterized by a higher CSF white cell count and also higher opening pressures [107,114–116]. Risk factors for cryptococcal IRIS include higher cryptococcal antigen titres at baseline, fungaemia or widely disseminated disease [107,108] and ART within 1 month of antifungal therapy [107,108]. The diagnosis of cryptococcal IRIS is partly one of exclusion, the following factors supporting this diagnosis:

- temporal association between starting ART and clinical presentation
- evidence of immune restoration (rise in peripheral CD4 cell count)
- exclusion of alternative explanations (e.g., noncompliance or resistance to fluconazole, a second possible diagnosis)

- clinical features (i.e., new or increased lymphadenopathy), cytology (i.e., CSF white cell count) or histopathology consistent with an increased cell-mediated immune response
- negative cryptococcal cultures (restricted definition).

The role of IRIS is less in doubt when cryptococcal cultures are negative, but it is likely that immune reconstitution also contributes to the presentation and re-presentation of some patients who are still culture positive [77].

The occurrence of cryptococcal IRIS has implications for the timing of ART. The apparent increase in the risk of cryptococcal IRIS with earlier initiation of ART has to be balanced against the risk of other HIV-related complications if initiation of ART is delayed. Optimal timing of ART may be earlier in developing countries where rates of death prior to initiation of ART are high [60,117]. Until trials currently underway report, most investigators would start ART from 4 weeks into antifungal therapy, although it is possible earlier ART may be safe if a rapidly fungicidal regimen is used for initial antifungal therapy. Treatment of cryptococcal IRIS is another area requiring further investigation. If clinical progression occurs, despite appropriate antifungal therapy and aggressive management of any raised CSF pressure, short-term steroids, which have been used successfully in case reports [108,118,119], can be considered.

Prevention and screening

The need for primary antifungal prophylaxis is reducing as access to ART expands, the best prophylaxis being rapid immune reconstitution with ART. However in the absence of ART, or in those who fail to respond to treatment, a strong case exists for primary prophylaxis with fluconazole in those with CD4 cell counts < 100 cells/ μ l in areas with a high incidence of cryptococcal disease [120,121]. Such a policy was introduced in Thailand prior to widespread availability of ART and is under investigation in east Africa. In areas of high incidence, in view of the significant proportion of patients now presenting after starting ART [60], a case can also be made for screening with serum cryptococcal antigen [122] prior to ART in order to diagnose and treat subclinical infection before it is unmasked by immune reconstitution. However, studies are needed, and such a strategy is not justified and is not used in areas of lower incidence [18,123].

Future developments

Reasons for the ongoing high mortality of HIV-related cryptococcal disease include the inadequacy of current antifungal therapy, restricted access to some drugs in many areas [124], the problem of raised CSF pressure and the lack

of data on optimal timing of ART. As discussed above, efforts are underway to address some of these questions.

Regarding access to antifungal drugs, fluconazole is widely available through a free access programme and in generic form. In contrast, although generic amphotericin B is also available, the cost is variable and may be significant in very resource-limited settings [124]. In addition, continuous supply has been an issue in some areas, including the United Kingdom, related perhaps to the reduced market for amphotericin B deoxycholate for treating other fungal infections in the developed world. Flucytosine is a simple and old molecule that nevertheless is not widely available either in Africa or Asia, where the burden of cryptococcal disease is so high. Only one manufacturer markets the drug to our knowledge. In countries where they are not marketed, flucytosine tablets can be obtained on a named patient basis from IDIS World Medicines (www.idispharma.com). If studies, currently underway, comparing high-dose fluconazole with flucytosine as a companion drug to give with amphotericin B show that flucytosine remains the second drug of choice, then advocacy is needed to expand access to flucytosine.

The rate of clearance of infection, or early fungicidal activity, from serial quantitative cultures of CSF provides a means by which the activity of new drugs or combinations for antifungal therapy can be accurately assessed in small numbers of patients; this would enable regimens for testing in phase III trials to be selected on a more rational basis [20]. Such clearance studies are underway to examine whether 1 mg/kg amphotericin B daily is associated with a significant increase in fungicidal activity compared with 0.7 mg/kg daily, and to compare flucytosine and high-dose fluconazole as a second drug to give with amphotericin B. Comparative studies are also needed with new azoles with activity against *C. neoformans*, such as voriconazole [125], although interactions with antituberculous and antiretroviral medication are a problem. Minimal inhibitory concentrations, animal model data and penetration into the central nervous system for voriconazole and posaconazole are shown in Table 2. Of note, echinocandins have limited anticryptococcal activity because they target 1–3- β -D-glucan linkages, which are not important in the cryptococcal cell wall [126].

Given the limitations of current antifungal drugs, and uncertainty over further drug development, there is continuing interest in adjunctive immunotherapy. A monoclonal antibody directed against the capsular polysaccharide of *C. neoformans* has reached phase I human studies [127]; and a monoclonal antibody fragment, Mycograb, directed against candidal heat shock protein 90, and reported to be beneficial when given with amphotericin B in invasive candidiasis [128], also has in-vitro activity against *C. neoformans* [129]. Clinical trials in cryptococcal meningitis are planned.

Table 2. Data on activity of posaconazole and voriconazole in cryptococcal infection.

	Posaconazole [134]	Voriconazole
In-vitro minimum concentration giving 90% inhibition ($\mu\text{g/ml}$) ^a [135–144]	0.25–0.5	0.12–0.25
Activity against fluconazole-resistant strains Animal models	Yes [135–140] Equivalent efficacy to fluconazole in rabbit model [140]; active in murine model; at doses tested but appeared inferior to amphotericin B [145]	Yes [141–144] Good activity in murine model [146], in high doses equivalent efficacy to amphotericin B [147]
Penetration into CSF ^b	Poor; undetectable levels in CSF in animal models, despite therapeutic plasma levels and in-vivo efficacy [140]	Good; high levels demonstrated in CSF in animal models and immunosuppressed patients [148]
Penetration into brain tissue	No data	High levels demonstrated in guinea pig models and immunosuppressed patients [148]
Clinical data	Case series of activity in fungal CNS infections [149,150]; clinical success in 14 of 29 patients (48%) ^c with refractory cryptococcal meningitis [150]	Case series of activity in fungal CNS infections [151,152]; successful response in 7 of 18 (39%) patients ^d with refractory cryptococcal meningitis [125]

CSF, cerebrospinal fluid; CNS, central nervous system.

^aFor comparison, values for itraconazole and fluconazole are 0.5 and 8–16 $\mu\text{g/ml}$, respectively.

^bRelevance unclear given the concentration of amphotericin B, a very active drug, is very low in CSF [153,154].

^cSuccess required resolution of (seen in 4 patients) or improvement in (10 patients) attributable symptoms, signs and radiographic abnormalities; all successes also had negative CSF culture; of the other 15 patients, 6 classified as stable.

^dSuccess required demonstration of reduction in antigen titre; of other 11 patients, 10 classified as stable; > 90% patients alive at 90 days.

An alternative approach is use of interferon- γ (IFN- γ). There is direct in-vivo evidence that IFN- γ is important for clearance of cryptococcal infection in HIV-infected patients [130]. A placebo-controlled trial showed that adjuvant IFN- γ therapy was safe and well tolerated, with no detrimental effects on HIV viral load or CD4 cell counts. There was also a trend towards improved mycological outcomes, with 13% of placebo recipients achieving negative cultures at 2 weeks compared with 36% or 32% of those receiving IFN- γ [131]. The trend in favour of IFN- γ was already seen after 2 weeks of treatment, and studies have shown that endogenous IFN- γ in the CSF peaks at day 3 and is virtually undetectable by day 14 [130], suggesting that short courses of adjuvant IFN- γ , which would be more feasible to implement, may be effective.

Finally, studies continue to identify suitable cryptococcal antigens for vaccine development [132] and to address the formidable challenges inherent in the vaccination of immunodeficient hosts, such as those with HIV infection [133].

References

- Morgan J, McCarthy KM, Gould S, Fan K, Arthington-Skaggs B, Iqbal N, et al. **Cryptococcus gattii** infection: characteristics and epidemiology of cases identified in a South African province with high HIV seroprevalence, 2002–2004. *Clin Infect Dis* 2006; **43**:1077–1080.
- Chayakulkeeree M, Perfect JR. **Cryptococcosis**. *Infect Dis Clin North Am* 2006; **20**:507–544; v-vi.
- Lindberg J, Hagen F, Laursen A, Stenderup J, Boekhout T. **Cryptococcus gattii** risk for tourists visiting Vancouver Island, Canada. *Emerg Infect Dis* 2007; **13**:178–179.
- Galanis E, MacDougall L, Li M, Kidd S, Lee M, Morshed M. **Clinical and epidemiological aspects of locally acquired *Cryptococcus gattii* human infections, an emerging fungal pathogen in British Columbia, Canada**. 17th European Congress of Clinical Microbiology and Infectious Diseases. Munich, April 2007 [abstract O170].
- Lazera MS, Salmito Cavalcanti MA, Londero AT, Trilles L, Nishikawa MM, Wanke B, et al. **Possible primary ecological niche of *Cryptococcus neoformans***. *Med Mycol* 2000; **38**:379–383.
- Randhawa HS, Kowshik T, Preeti Sinha K, Chowdhary A, Khan ZU, Yan Z, et al. **Distribution of *Cryptococcus gattii* and *Cryptococcus neoformans* in decayed trunk wood of *Syzygium cumini* trees in north-western India**. *Med Mycol* 2006; **44**:623–630.
- Swinne D, Deppner M, Laroche R, Floch JJ, Kadende P. **Isolation of *Cryptococcus neoformans* from houses of AIDS-associated cryptococcosis patients in Bujumbura (Burundi)**. *AIDS* 1989; **3**:389–390.
- Swinne D, Taelman H, Batungwanayo J, Bigirankana A, Bogaerts J. **Ecology of *Cryptococcus neoformans* in central Africa**. *Med Trop (Mars)* 1994; **54**:53–55.
- Goldman DL, Khine H, Abadi J, Lindenberg DJ, Pirofski L, Niang R, et al. **Serologic evidence for *Cryptococcus neoformans* infection in early childhood**. *Pediatrics* 2001; **107**:E66.
- Wickes BL, Mayorga ME, Edman U, Edman JC. **Dimorphism and haploid fruiting in *Cryptococcus neoformans*: association with the alpha-mating type**. *Proc Natl Acad Sci USA* 1996; **93**:7327–7331.
- Hung JJ, Ou LS, Lee WI, Huang JL. **Central nervous system infections in patients with systemic lupus erythematosus**. *J Rheumatol* 2005; **32**:40–43.
- Ross JJ, Katz JD. **Cryptococcal meningitis and sarcoidosis**. *Scand J Infect Dis* 2002; **34**:937–939.
- Goldman DL, Lee SC, Mednick AJ, Montella L, Casadevall A. **Persistent *Cryptococcus neoformans* pulmonary infection in the rat is associated with intracellular parasitism, decreased inducible nitric oxide synthase expression, and altered antibody responsiveness to cryptococcal polysaccharide**. *Infect Immun* 2000; **68**:832–838.
- Salyer WR, Salyer DC, Baker RD. **Primary complex of *Cryptococcus* and pulmonary lymph nodes**. *J Infect Dis* 1974; **130**:74–77.

15. Garcia-Hermoso D, Janbon G, Dromer F. **Epidemiological evidence for dormant *Cryptococcus neoformans* infection.** *J Clin Microbiol* 1999; **37**:3204–3209.
16. Fessel WJ. **Cryptococcal meningitis after unusual exposures to birds.** *N Engl J Med* 1993; **328**:1354–1355.
17. MacDougall L, Fyfe M. **Emergence of *Cryptococcus gattii* in a novel environment provides clues to its incubation period.** *J Clin Microbiol* 2006; **44**:1851–1852.
18. Feldmesser M, Harris C, Reichberg S, Khan S, Casadevall A. **Serum cryptococcal antigen in patients with AIDS.** *Clin Infect Dis* 1996; **23**:827–830.
19. Saag MS, Powderly WG, Cloud GA, Robinson P, Grieco MH, Sharkey PK, et al. **Comparison of amphotericin B with fluconazole in the treatment of acute AIDS-associated cryptococcal meningitis. The NIAID Mycoses Study Group and the AIDS Clinical Trials Group.** *N Engl J Med* 1992; **326**:83–89.
20. Brouwer AE, Rajanuwong A, Chierakul W, Griffin GE, Larsen RA, White NJ, et al. **Combination antifungal therapies for HIV-associated cryptococcal meningitis: a randomised trial.** *Lancet* 2004; **363**:1764–1767.
21. van der Horst CM, Saag MS, Cloud GA, Hamill RJ, Graybill JR, Sobel JD, et al. **Treatment of cryptococcal meningitis associated with the acquired immunodeficiency syndrome. National Institute of Allergy and Infectious Diseases Mycoses Study Group and AIDS Clinical Trials Group.** *N Engl J Med* 1997; **337**:15–21.
22. Graybill JR, Sobel J, Saag M, van Der Horst C, Powderly W, Cloud G, et al. **Diagnosis and management of increased intracranial pressure in patients with AIDS and cryptococcal meningitis. The NIAID Mycoses Study Group and AIDS Cooperative Treatment Groups.** *Clin Infect Dis* 2000; **30**:47–54.
23. Lee SC, Casadevall A. **Polysaccharide antigen in brain tissue of AIDS patients with cryptococcal meningitis.** *Clin Infect Dis* 1996; **23**:194–195.
24. Lee SC, Casadevall A, Dickson DW. **Immunohistochemical localization of capsular polysaccharide antigen in the central nervous system cells in cryptococcal meningoencephalitis.** *Am J Pathol* 1996; **148**:1267–1274.
25. Lee SC, Dickson DW, Casadevall A. **Pathology of cryptococcal meningoencephalitis: analysis of 27 patients with pathogenetic implications.** *Hum Pathol* 1996; **27**:839–847.
26. Molez JF, Ginoux PY, Asselin P, Frezil JL. **Demonstration of *Cryptococcus neoformans* in a fatal meningeal disease in the Congo.** *Med Trop (Mars)* 1982; **42**:561–563.
27. Molez JF. **The historical question of acquired immunodeficiency syndrome in the 1960s in the Congo River basin area in relation to cryptococcal meningitis.** *Am J Trop Med Hyg* 1998; **58**:273–276.
28. Lamey B, Melameka N. **Clinical and epidemiologic aspects of cryptococcosis in Kinshasa. Apropos of 15 personal cases.** *Med Trop (Mars)* 1982; **42**:507–511.
29. Swinne D, Kayembe K, Niyimi M. **Isolation of saprophytic *Cryptococcus neoformans* var. *neoformans* in Kinshasa, Zaire.** *Ann Soc Belg Med Trop* 1986; **66**:57–61.
30. Clumeck N, Mascart-Lemone F, de Maubeuge J, Brenez D, Marcelis L. **Acquired immune deficiency syndrome in Black Africans.** *Lancet* 1983; **i**:642.
31. Brunet JB, Bouvet E, Leibowitch J, Chaperon J, Mayaud C, Gluckman JC, et al. **Acquired immunodeficiency syndrome in France.** *Lancet* 1983; **i**:700–701.
32. Offenstadt G, Pinta P, Hericord P, Jagueux M, Jean F, Amstutz P, et al. **Multiple opportunistic infection due to AIDS in a previously healthy black woman from Zaire.** *N Engl J Med* 1983; **308**:775.
33. Vandepitte J, Verwilghen R, Zachee P. **AIDS and cryptococcosis (Zaire, 1977).** *Lancet* 1983; **i**:925–926.
34. Selik RM, Karon JM, Ward JW. **Effect of the human immunodeficiency virus epidemic on mortality from opportunistic infections in the United States in 1993.** *J Infect Dis* 1997; **176**:632–636.
35. Sorvillo F, Beall G, Turner PA, Beer VL, Kovacs AA, Kerndt PR. **Incidence and factors associated with extrapulmonary cryptococcosis among persons with HIV infection in Los Angeles County.** *AIDS* 1997; **11**:673–679.
36. Dore GJ, Hoy JF, Mallal SA, Li Y, Mijch AM, French MA, et al. **Trends in incidence of AIDS illnesses in Australia from 1983 to 1994: the Australian AIDS cohort.** *J Acquir Immune Defic Syndr Hum Retrovirology* 1997; **16**:39–43.
37. Chuck SL, Sande MA. **Infections with *Cryptococcus neoformans* in the acquired immunodeficiency syndrome.** *N Engl J Med* 1989; **321**:794–799.
38. Hajjeh RA, Conn LA, Stephens DS, Baughman W, Hamill R, Graviss E, et al. **Cryptococcosis: population-based multistate active surveillance and risk factors in human immunodeficiency virus-infected persons. Cryptococcal Active Surveillance Group.** *J Infect Dis* 1999; **179**:449–454.
39. Chen S, Sorrell T, Nimmo G, Speed B, Currie B, Ellis D, et al. **Epidemiology and host- and variety-dependent characteristics of infection due to *Cryptococcus neoformans* in Australia and New Zealand. Australasian Cryptococcal Study Group.** *Clin Infect Dis* 2000; **31**:499–508.
40. Kaplan JE, Hanson D, Dworkin MS, Frederick T, Bertolli J, Lindgren ML, et al. **Epidemiology of human immunodeficiency virus-associated opportunistic infections in the United States in the era of highly active antiretroviral therapy.** *Clin Infect Dis* 2000; **30** (Suppl 1):S5–S14.
41. Mirza SA, Phelan M, Rimland D, Graviss E, Hamill R, Brandt ME, et al. **The changing epidemiology of cryptococcosis: an update from population-based active surveillance in 2 large metropolitan areas, 1992–2000.** *Clin Infect Dis* 2003; **36**:789–794.
42. Holmes CB, Losina E, Walensky RP, Yazdanpanah Y, Freedberg KA. **Review of human immunodeficiency virus type 1-related opportunistic infections in sub-Saharan Africa.** *Clin Infect Dis* 2003; **36**:652–662.
43. Chariyalertsak S, Sirisanthana T, Saengwonloy O, Nelson KE. **Clinical presentation and risk behaviors of patients with acquired immunodeficiency syndrome in Thailand, 1994–1998: regional variation and temporal trends.** *Clin Infect Dis* 2001; **32**:955–962.
44. Gordon SB, Walsh AL, Chaponda M, Gordon MA, Soko D, Mbwvinji M, et al. **Bacterial meningitis in Malawian adults: pneumococcal disease is common, severe, and seasonal.** *Clin Infect Dis* 2000; **31**:53–57.
45. Bekondi C, Bernede C, Passone N, Minssart P, Kamalo C, Mbolidi D, et al. **Primary and opportunistic pathogens associated with meningitis in adults in Bangui, Central African Republic, in relation to human immunodeficiency virus serostatus.** *Int J Infect Dis* 2006; **10**:387–395.
46. Hakim JG, Gangaidzo IT, Heyderman RS, Mielke J, Mushangi E, Taziwa A, et al. **Impact of HIV infection on meningitis in Harare, Zimbabwe: a prospective study of 406 predominantly adult patients.** *AIDS* 2000; **14**:1401–1407.
47. Okongo M, Morgan D, Mayanja B, Ross A, Whitworth J. **Causes of death in a rural, population-based human immunodeficiency virus type 1 (HIV-1) natural history cohort in Uganda.** *Int J Epidemiol* 1998; **27**:698–702.
48. French N, Gray K, Watera C, Nakiyingi J, Lugada E, Moore M, et al. **Cryptococcal infection in a cohort of HIV-1-infected Ugandan adults.** *AIDS* 2002; **16**:1031–1038.
49. Corbett EL, Churchyard GJ, Charalambos S, Samb B, Moloi V, Clayton TC, et al. **Morbidity and mortality in South African gold miners: impact of untreated disease due to human immunodeficiency virus.** *Clin Infect Dis* 2002; **34**:1251–1258.
50. Suwanagoon S, Ratanasuwan W. **AIDS at Siriraj Hospital during 1985–1993.** *J Infect Dis Antimicrob Agents* 1994; **11**:117–124.
51. Kumarasamy N, Solomon S, Flanigan TP, Hemalatha R, Thyagarajan SP, Mayer KH. **Natural history of human immunodeficiency virus disease in southern India.** *Clin Infect Dis* 2003; **36**:79–85.
52. Pappalardo MC, Melhem MS. **Cryptococcosis: a review of the Brazilian experience for the disease.** *Rev Inst Med Trop Sao Paulo* 2003; **45**:299–305.
53. Lucas SB, Hounnou A, Peacock C, Beaumel A, Djomand G, N'Gbichi JM, et al. **The mortality and pathology of HIV infection in a west African city.** *AIDS* 1993; **7**:1569–1579.
54. Lortholary O, Poizat G, Zeller V, Neuville S, Boibieux A, Alvarez M, et al. **Long-term outcome of AIDS-associated cryptococcosis in the era of combination antiretroviral therapy.** *AIDS* 2006; **20**:2183–2191.
55. Robinson PA, Bauer M, Leal MA, Evans SG, Holtom PD, Diamond DA, et al. **Early mycological treatment failure in AIDS-associated cryptococcal meningitis.** *Clin Infect Dis* 1999; **28**:82–92.
56. Imwidthaya P, Pongvarin N. **Cryptococcosis in AIDS.** *Postgrad Med J* 2000; **76**:85–88.

57. Mwaba P, Mwansa J, Chintu C, Pobee J, Scarborough M, Portsmouth S, *et al.* **Clinical presentation, natural history, and cumulative death rates of 230 adults with primary cryptococcal meningitis in Zambian AIDS patients treated under local conditions.** *Postgrad Med J* 2001; **77**:769–773.
58. Maher D, Mwandumba H. **Cryptococcal meningitis in Lilongwe and Blantyre, Malawi.** *J Infect* 1994; **28**:59–64.
59. Heyderman RS, Gangaidzo IT, Hakim JG, Mielke J, Taziwa A, Musvaire P, *et al.* **Cryptococcal meningitis in human immunodeficiency virus-infected patients in Harare, Zimbabwe.** *Clin Infect Dis* 1998; **26**:284–289.
60. Bicanic T, Meintjes G, Wood R, Hayes M, Rebe K, Bekker LG, *et al.* **Fungal burden, early fungicidal activity, and outcome in cryptococcal meningitis in antiretroviral-naïve or -experienced patients treated with amphotericin B or fluconazole.** *Clin Infect Dis* 2007; **45**:76–80.
61. Saag MS, Graybill RJ, Larsen RA, Pappas PG, Perfect JR, Powderly WG, *et al.* **Practice guidelines for the management of cryptococcal disease.** *Infectious Diseases Society of America.* *Clin Infect Dis* 2000; **30**:710–718.
62. Denning DW, Kibbler CC, Barnes RA. **British Society for Medical Mycology proposed standards of care for patients with invasive fungal infections.** *Lancet Infect Dis* 2003; **3**:230–240.
63. Branch RA. **Prevention of amphotericin B-induced renal impairment. A review on the use of sodium supplementation.** *Arch Intern Med* 1988; **148**:2389–2394.
64. Yeo EJ, Ryu JH, Cho YS, Chun YS, Huang LE, Kim MS, *et al.* **Amphotericin B blunts erythropoietin response to hypoxia by reinforcing FIH-mediated repression of HIF-1.** *Blood* 2006; **107**:916–923.
65. Utz JP. **Amphotericin B toxicity: general side effects.** *Ann Intern Med* 1964; **61**:340–343.
66. Brandiss MW. **Amphotericin B toxicity: anemia.** *Ann Intern Med* 1964; **61**:343–344.
67. Brandiss MW, Wolff SM, Moores R, Stohlman F Jr. **Anemia induced by Amphotericin B.** *JAMA* 1964; **189**:663–666.
68. Brouwer AE, van Kan HJ, Johnson E, Rajanuwong A, Teparukkul P, Wuthiekanun V, *et al.* **Oral versus intravenous flucytosine in patients with human immunodeficiency virus-associated cryptococcal meningitis.** *Antimicrob Agents Chemother* 2007; **51**:1038–1042.
69. Andes D, van Ogtrop M. **In vivo characterization of the pharmacodynamics of flucytosine in a neutropenic murine disseminated candidiasis model.** *Antimicrob Agents Chemother* 2000; **44**:938–942.
70. Francis P, Walsh TJ. **Evolving role of flucytosine in immunocompromised patients: new insights into safety, pharmacokinetics, and antifungal therapy.** *Clin Infect Dis* 1992; **15**:1003–1018.
71. Lewis RE, Klepser ME, Pfaller MA. **In vitro pharmacodynamic characteristics of flucytosine determined by time-kill methods.** *Diagn Microbiol Infect Dis* 2000; **36**:101–105.
72. Leenders AC, Reiss P, Portegies P, Clezy K, Hop WC, Hoy J, *et al.* **Liposomal amphotericin B (AmBisome) compared with amphotericin B both followed by oral fluconazole in the treatment of AIDS-associated cryptococcal meningitis.** *AIDS* 1997; **11**:1463–1471.
73. Hamill RJ, Sobel J, el-Sadr W, *et al.* **Randomized double blind trial of AmBisome (liposomal amphotericin B) and amphotericin B in acute cryptococcal meningitis in AIDS patients.** *39th Interscience Conference on Antimicrobial Agents and Chemotherapy.* San Francisco, September 1999 [abstract 1161].
74. Larsen RA, Leal MA, Chan LS. **Fluconazole compared with amphotericin B plus flucytosine for cryptococcal meningitis in AIDS. A randomized trial.** *Ann Intern Med* 1990; **113**:183–187.
75. Schaars CF, Meintjes GA, Morroni C, Post FA, Maartens G. **Outcome of AIDS-associated cryptococcal meningitis initially treated with 200 mg/day or 400 mg/day of fluconazole.** *BMC Infect Dis* 2006; **6**:118.
76. Mayanja-Kizza H, Oishi K, Mitarai S, Yamashita H, Nalongo K, Watanabe K, *et al.* **Combination therapy with fluconazole and flucytosine for cryptococcal meningitis in Ugandan patients with AIDS.** *Clin Infect Dis* 1998; **26**:1362–1366.
77. Bicanic T, Harrison T, Niepieklo A, Dyakopu N, Meintjes G. **Symptomatic relapse of HIV-associated cryptococcal meningitis after initial fluconazole monotherapy: the role of fluconazole resistance and immune reconstitution.** *Clin Infect Dis* 2006; **43**:1069–1073.
78. Kartalija M, Kaye K, Tureen JH, Liu Q, Tauber MG, Elliott BR, *et al.* **Treatment of experimental cryptococcal meningitis with fluconazole: impact of dose and addition of flucytosine on mycologic and pathophysiologic outcome.** *J Infect Dis* 1996; **173**:1216–1221.
79. Anaissie EJ, Kontoyiannis DP, Huls C, Vartivarian SE, Karl C, Prince RA, *et al.* **Safety, plasma concentrations, and efficacy of high-dose fluconazole in invasive mold infections.** *J Infect Dis* 1995; **172**:599–602.
80. Milechik E, Leal M, Haubrich R. **A phase II dose escalation trial of high dose fluconazole with and without flucytosine for AIDS-associated cryptococcal meningitis.** *Fourth Conference on Retroviruses and Opportunistic Infections.* Washington DC, January 1997 [abstract 5].
81. Haubrich RH, Haghight D, Bozzette SA, Tilles J, McCutchan JA. **High-dose fluconazole for treatment of cryptococcal disease in patients with human immunodeficiency virus infection.** *The California Collaborative Treatment Group.* *J Infect Dis* 1994; **170**:238–242.
82. Menichetti F, Fiorio M, Tosti A, Gatti G, Bruna Pasticci M, Miletich F, *et al.* **High-dose fluconazole therapy for cryptococcal meningitis in patients with AIDS.** *Clin Infect Dis* 1996; **22**:838–840.
83. Allendoerfer R, Marquis AJ, Rinaldi MG, Graybill JR. **Combined therapy with fluconazole and flucytosine in murine cryptococcal meningitis.** *Antimicrob Agents Chemother* 1991; **35**:726–729.
84. Ding JC, Bauer M, Diamond DM, Leal MA, Johnson D, Williams BK, *et al.* **Effect of severity of meningitis on fungicidal activity of flucytosine combined with fluconazole in a murine model of cryptococcal meningitis.** *Antimicrob Agents Chemother* 1997; **41**:1589–1593.
85. Larsen RA, Bozzette SA, Jones BE, Haghight D, Leal MA, Forthal D, *et al.* **Fluconazole combined with flucytosine for treatment of cryptococcal meningitis in patients with AIDS.** *Clin Infect Dis* 1994; **19**:741–745.
86. Bozzette SA, Larsen RA, Chiu J, Leal MA, Jacobsen J, Rothman P, *et al.* **A placebo-controlled trial of maintenance therapy with fluconazole after treatment of cryptococcal meningitis in the acquired immunodeficiency syndrome.** *California Collaborative Treatment Group.* *N Engl J Med* 1991; **324**:580–584.
87. Powderly WG, Saag MS, Cloud GA, Robinson P, Meyer RD, Jacobson JM, *et al.* **A controlled trial of fluconazole or amphotericin B to prevent relapse of cryptococcal meningitis in patients with the acquired immunodeficiency syndrome.** *The NIAID AIDS Clinical Trials Group and Mycoses Study Group.* *N Engl J Med* 1992; **326**:793–798.
88. Saag MS, Cloud GA, Graybill JR, Sobel JD, Tuazon CU, Johnson PC, *et al.* **A comparison of itraconazole versus fluconazole as maintenance therapy for AIDS-associated cryptococcal meningitis.** *National Institute of Allergy and Infectious Diseases Mycoses Study Group.* *Clin Infect Dis* 1999; **28**:291–296.
89. Aberg JA, Price RW, Heeren DM, Bredt B. **A pilot study of the discontinuation of antifungal therapy for disseminated cryptococcal disease in patients with acquired immunodeficiency syndrome, following immunologic response to antiretroviral therapy.** *J Infect Dis* 2002; **185**:1179–1182.
90. Vibhagool A, Sungkanuparph S, Mootsikapun P, Chetchotisakd P, Tansuphaswaswadikul S, Bowonwatanuwong C, *et al.* **Discontinuation of secondary prophylaxis for cryptococcal meningitis in human immunodeficiency virus-infected patients treated with highly active antiretroviral therapy: a prospective, multicenter, randomized study.** *Clin Infect Dis* 2003; **36**:1329–1331.
91. Mussini C, Pezzotti P, Miro JM, Martinez E, de Quiros JC, Cinque P, *et al.* **Discontinuation of maintenance therapy for cryptococcal meningitis in patients with AIDS treated with highly active antiretroviral therapy: an international observational study.** *Clin Infect Dis* 2004; **38**:565–571.
92. Denning DW, Armstrong RW, Lewis BH, Stevens DA, *et al.* **Elevated cerebrospinal fluid pressures in patients with cryptococcal meningitis and acquired immunodeficiency syndrome.** *Am J Med* 1991; **91**:267–272.
93. Rex JH, Larsen RA, Dismukes WE, Cloud GA, Bennett JE. **Catastrophic visual loss due to *Cryptococcus neoformans* meningitis.** *Medicine (Baltimore)* 1993; **72**:207–224.

94. Bach MC, Tally PW, Godofsky EW. **Use of cerebrospinal fluid shunts in patients having acquired immunodeficiency syndrome with cryptococcal meningitis and uncontrollable intracranial hypertension.** *Neurosurgery* 1997; **41**:1280–1282; [Discussion 1282–1283.]
95. Hoepelman AI, van der Flier M, Coenjaerts FE. **Dexamethasone downregulates *Cryptococcus neoformans*-induced vascular endothelial growth factor production: a role for corticosteroids in cryptococcal meningitis?.** *J Acquir Immune Defic Syndr* 2004; **37**:1431–1432.
96. Coenjaerts FE, van der Flier M, Mwinzi PN, Brouwer AE, Scharringa J, Chaka WS, et al. **Intrathecal production and secretion of vascular endothelial growth factor during cryptococcal meningitis.** *J Infect Dis* 2004; **190**:1310–1317.
97. Sun HY, Hung CC, Chang SC. **Management of cryptococcal meningitis with extremely high intracranial pressure in HIV-infected patients.** *Clin Infect Dis* 2004; **38**:1790–1792.
98. Park MK, Hospenthal DR, Bennett JE. **Treatment of hydrocephalus secondary to cryptococcal meningitis by use of shunting.** *Clin Infect Dis* 1999; **28**:629–633.
99. Macsween KF, Bicanic T, Brouwer AE, Marsh H, Macallan DC, Harrison TS. **Lumbar drainage for control of raised cerebrospinal fluid pressure in cryptococcal meningitis: case report and review.** *J Infect* 2005; **51**:e221–e224.
100. Fessler RD, Sobel J, Guyot L, Crane L, Vazquez J, Szuba MJ, et al. **Management of elevated intracranial pressure in patients with cryptococcal meningitis.** *J Acquir Immune Defic Syndr Hum Retroviro* 1998; **17**:137–142.
101. Coplin WM, Avellino AM, Kim DK, Winn HR, Grady MS. **Bacterial meningitis associated with lumbar drains: a retrospective cohort study.** *J Neurol Neurosurg Psychiatry* 1999; **67**:468–473.
102. American Association of Neuroscience Nurses. *Care of the Patient with a Lumbar Drain.* [AANN Reference Series for Clinical Practice.] Glenview, IL: American Association of Neuroscience Nurses; 2007:1–15.
103. Newton PN, Thai le H, Tip NQ, Short JM, Chierakul W, Rajanuwong A, et al. **A randomized, double-blind, placebo-controlled trial of acetazolamide for the treatment of elevated intracranial pressure in cryptococcal meningitis.** *Clin Infect Dis* 2002; **35**:769–772.
104. Robertson J, Meier M, Wall J, Ying J, Fichtenbaum CJ. **Immune reconstitution syndrome in HIV: validating a case definition and identifying clinical predictors in persons initiating antiretroviral therapy.** *Clin Infect Dis* 2006; **42**:1639–1646.
105. Ratnam I, Chiu C, Kandala NB, Easterbrook PJ. **Incidence and risk factors for immune reconstitution inflammatory syndrome in an ethnically diverse HIV type 1-infected cohort.** *Clin Infect Dis* 2006; **42**:418–427.
106. Lawn SD, Bekker LG, Miller RF. **Immune reconstitution disease associated with mycobacterial infections in HIV-infected individuals receiving antiretrovirals.** *Lancet Infect Dis* 2005; **5**:361–373.
107. Shelburne SA III, Darcourt J, White AC Jr, Greenberg SB, Hamill RJ, Atmar RL, et al. **The role of immune reconstitution inflammatory syndrome in AIDS-related *Cryptococcus neoformans* disease in the era of highly active antiretroviral therapy.** *Clin Infect Dis* 2005; **40**:1049–1052.
108. Lortholary O, Fontanet A, Mémain N, Martin A, Sitbon K, Dromer F. **Incidence and risk factors of immune reconstitution inflammatory syndrome complicating HIV-associated cryptococcosis in France.** *AIDS* 2005; **19**:1043–1049.
109. Lawn SD, Bekker LG, Myer L, Orrell C, Wood R. **Cryptococcal immune reconstitution disease: a major cause of early mortality in a South African antiretroviral programme.** *AIDS* 2005; **19**:2050–2052.
110. Trevenzoli M, Cattelan AM, Rea F, Sasset L, Semisa M, Lanzafame M, et al. **Mediastinitis due to cryptococcal infection: a new clinical entity in the HAART era.** *J Infect* 2002; **45**:173–179.
111. Manfredi R, Pieri F, Pileri SA, Chiodo F. **The changing face of AIDS-related opportunism: cryptococcosis in the highly active antiretroviral therapy (HAART) era. Case reports and literature review.** *Mycopathologia* 1999; **148**:73–78.
112. Cattelan AM, Trevenzoli M, Sasset L, Lanzafame M, Marchioro U, Meneghetti F. **Multiple cerebral cryptococcomas associated with immune reconstitution in HIV-1 infection.** *AIDS* 2004; **18**:349–351.
113. Jenny-Avital ER, Abadi M. **Immune reconstitution cryptococcosis after initiation of successful highly active antiretroviral therapy.** *Clin Infect Dis* 2002; **35**:e128–e133.
114. Woods ML II, MacGinley R, Eisen DP, Allworth AM. **HIV combination therapy: partial immune restitution unmasking latent cryptococcal infection.** *AIDS* 1998; **12**:1491–1494.
115. Shelburne SA III, Hamill RJ. **The immune reconstitution inflammatory syndrome.** *AIDS Rev* 2003; **5**:67–79.
116. York J, Bodi I, Reeves I, Riordan-Eva P, Easterbrook PJ. **Raised intracranial pressure complicating cryptococcal meningitis: immune reconstitution inflammatory syndrome or recurrent cryptococcal disease?** *J Infect* 2005; **51**:165–171.
117. Lawn SD, Myer L, Orrell C, Bekker LG, Wood R. **Early mortality among adults accessing a community-based antiretroviral service in South Africa: implications for programme design.** *AIDS* 2005; **19**:2141–2148.
118. Shelburne SA III, Hamill RJ, Rodriguez-Barradas MC, Greenberg SB, Atmar RL, Musher DW, et al. **Immune reconstitution inflammatory syndrome: emergence of a unique syndrome during highly active antiretroviral therapy.** *Medicine (Baltimore)* 2002; **81**:213–227.
119. Boelaert JR, Goddeeris KH, Vanopdenbosch LJ, Casselman JW. **Relapsing meningitis caused by persistent cryptococcal antigens and immune reconstitution after the initiation of highly active antiretroviral therapy.** *AIDS* 2004; **18**:1223–1224.
120. Chetchotisakd P, Sungkanuparph S, Thinkhamrop B, Mootsikapun P, Boonyaprawit P. **A multicentre, randomized, double-blind, placebo-controlled trial of primary cryptococcal meningitis prophylaxis in HIV-infected patients with severe immune deficiency.** *HIV Med* 2004; **5**:140–143.
121. Chang LW, Phipps WT, Kennedy GE, Ruthefors GW. **Antifungal interventions for the primary prevention of cryptococcal disease in adults with HIV.** In *The Cochrane Database of Systematic Reviews*, Issue 3. Chichester, UK: John Wiley; 2005:CD004773.
122. Tassie JM, Pepper L, Fogg C, Biraro S, Mayanja B, Andia I, et al. **Systematic screening of cryptococcal antigenemia in HIV-positive adults in Uganda.** *J Acquir Immune Defic Syndr* 2003; **33**:411–412.
123. Hoffmann S, Stenderup J, Mathiesen LR. **Low yield of screening for cryptococcal antigen by latex agglutination assay on serum and cerebrospinal fluid from Danish patients with AIDS or ARC.** *Scand J Infect Dis* 1991; **23**:697–702.
124. Bicanic T, Wood R, Bekker LG, Darder M, Meintjes G, Harrison TS. **Antiretroviral roll-out, antifungal roll-back: access to treatment for cryptococcal meningitis.** *Lancet Infect Dis* 2005; **5**:530–531.
125. Perfect JR, Marr KA, Walsh TJ, Greenberg RN, DuPont B, de la Torre-Cisneros J, et al. **Voriconazole treatment for less-common, emerging, or refractory fungal infections.** *Clin Infect Dis* 2003; **36**:1122–1131.
126. Roling EE, Klepser ME, Wasson A, Lewis RE, Ernst EJ, Pfaller MA, et al. **Antifungal activities of fluconazole, caspofungin (MK0991), and anidulafungin (LY 303366) alone and in combination against *Candida* spp. and *Cryptococcus neoformans* via time-kill methods.** *Diagn Microbiol Infect Dis* 2002; **43**:13–17.
127. Larsen RA, Pappas PG, Perfect J, Aberg JA, Casadevall A, Cloud GA, et al. **Phase I evaluation of the safety and pharmacokinetics of murine-derived anticryptococcal antibody 18B7 in subjects with treated cryptococcal meningitis.** *Antimicrob Agents Chemother* 2005; **49**:952–958.
128. Matthews RC, Rigg G, Hodgetts S, Carter T, Chapman C, Gregory C, et al. **Preclinical assessment of the efficacy of mycograb, a human recombinant antibody against fungal HSP90.** *Antimicrob Agents Chemother* 2003; **47**:2208–2216.
129. Nooney L, Matthews RC, Burnie JP. **Evaluation of Mycograb, amphotericin B, caspofungin, and fluconazole in combination against *Cryptococcus neoformans* by checkerboard and time-kill methodologies.** *Diagn Microbiol Infect Dis* 2005; **51**:19–29.
130. Siddiqui AA, Brouwer AE, Wuthiekanun V, Jaffar S, Shattock R, Irving D, et al. **IFN-gamma at the site of infection determines rate of clearance of infection in cryptococcal meningitis.** *J Immunol* 2005; **174**:1746–1750.
131. Pappas PG, Bustamante B, Ticona E, Hamill RJ, Johnson PC, Reboli A, et al. **Recombinant interferon-gamma 1b as adjunctive therapy for AIDS-related acute cryptococcal meningitis.** *J Infect Dis* 2004; **189**:2185–2191.

132. Datta K, Pirofski LA. **Towards a vaccine for *Cryptococcus neoformans*: principles and caveats.** *FEMS Yeast Res* 2006; **6**:525–536.
133. Wuthrich M, Filutowicz HI, Warner T, Deepe GS Jr, Klein BS, et al. **Vaccine immunity to pathogenic fungi overcomes the requirement for CD4 help in exogenous antigen presentation to CD8+ T cells: implications for vaccine development in immune-deficient hosts.** *J Exp Med* 2003; **197**:1405–1416.
134. Torres HA, Hachem RY, Chemaly RF, Kontoyiannis DP, Raad II, et al. **Posaconazole: a broad-spectrum triazole antifungal.** *Lancet Infect Dis* 2005; **5**:775–785.
135. Pfaller MA, Messer SA, Boyken L, Rice C, Tendolkar S, Hollis RJ, et al. **Global trends in the antifungal susceptibility of *Cryptococcus neoformans* (1990 to 2004).** *J Clin Microbiol* 2005; **43**:2163–2167.
136. Barchiesi F, Arzeni D, Fothergill AW, Di Francesco LF, Caselli F, Rinaldi MG, et al. **In vitro activities of the new antifungal triazole SCH 56592 against common and emerging yeast pathogens.** *Antimicrob Agents Chemother* 2000; **44**:226–229.
137. Pfaller MA, Messer SA, Hollis RJ, Jones RN. **In vitro activities of posaconazole (Sch 56592) compared with those of itraconazole and fluconazole against 3685 clinical isolates of *Candida* spp. and *Cryptococcus neoformans*.** *Antimicrob Agents Chemother* 2001; **45**:2862–2864.
138. Pfaller MA, Messer SA, Boyken L, Hollis RJ, Rice C, Tendolkar S, et al. **In vitro activities of voriconazole, posaconazole, and fluconazole against 4169 clinical isolates of *Candida* spp. and *Cryptococcus neoformans* collected during 2001 and 2002 in the ARTEMIS global antifungal surveillance program.** *Diagn Microbiol Infect Dis* 2004; **48**:201–205.
139. Espinel-Ingroff A. **In vitro antifungal activities of anidulafungin and micafungin, licensed agents and the investigational triazole posaconazole as determined by NCCLS methods for 12 052 fungal isolates: review of the literature.** *Rev Iberoam Micol* 2003; **20**:121–136.
140. Perfect JR, Cox GM, Dodge RK, Schell WA, et al. **In vitro and in vivo efficacies of the azole SCH56592 against *Cryptococcus neoformans*.** *Antimicrob Agents Chemother* 1996; **40**:1910–1913.
141. Pfaller MA, Zhang J, Messer SA, Brandt ME, Hajjeh RA, Jessup CJ, et al. **In vitro activities of voriconazole, fluconazole, and itraconazole against 566 clinical isolates of *Cryptococcus neoformans* from the United States and Africa.** *Antimicrob Agents Chemother* 1999; **43**:169–171.
142. Klepser ME, Malone D, Lewis RE, Ernst EJ, Pfaller MA. **Evaluation of voriconazole pharmacodynamics using time-kill methodology.** *Antimicrob Agents Chemother* 2000; **44**:1917–1920.
143. van Duin D, Cleare W, Zaragoza O, Casadevall A, Nosanchuk JD. **Effects of voriconazole on *Cryptococcus neoformans*.** *Antimicrob Agents Chemother* 2004; **48**:2014–2020.
144. Nguyen MH, Yu CY. **In vitro comparative efficacy of voriconazole and itraconazole against fluconazole-susceptible and -resistant *Cryptococcus neoformans* isolates.** *Antimicrob Agents Chemother* 1998; **42**:471–472.
145. Barchiesi F, Spreghini E, Schimizzi AM, Maracci M, Giannini D, Carle F, et al. **Posaconazole and amphotericin B combination therapy against *Cryptococcus neoformans* infection.** *Antimicrob Agents Chemother* 2004; **48**:3312–3316.
146. Mavroggiorgos N, Zaragoza O, Casadevall A, Nosanchuk JD. **Efficacy of voriconazole in experimental *Cryptococcus neoformans* infection.** *Mycopathologia* 2006; **162**:111–114.
147. Serena C, Mariné M, Marimon R, Pastor FJ, Guarro J. **Efficacy of voriconazole in a murine model of cryptococcal central nervous system infection.** *J Antimicrob Chemother* 2007; **60**:162–165.
148. Lutsar I, Roffey S, Troke P. **Voriconazole concentrations in the cerebrospinal fluid and brain tissue of guinea pigs and immunocompromised patients.** *Clin Infect Dis* 2003; **37**:728–732.
149. Al-Abdely HM, Alkhunaizi AM, Al-Tawfiq JA, Hassounah M, Rinaldi MG, Sutton DA. **Successful therapy of cerebral phaeohyphomycosis due to *Ramichloridium mackenziei* with the new triazole posaconazole.** *Med Mycol* 2005; **43**:91–95.
150. Pitisuttithum P, Negroni R, Graybill JR, Bustamante B, Pappas P, Chapman S, et al. **Activity of posaconazole in the treatment of central nervous system fungal infections.** *J Antimicrob Chemother* 2005; **56**:745–755.
151. Schwartz S, Ruhnke M, Ribaud P, Corey L, Driscoll T, Cornely OA, et al. **Improved outcome in central nervous system aspergillosis, using voriconazole treatment.** *Blood* 2005; **106**:2641–2645.
152. Bakleh M, Aksamit AJ, Tleyjeh IM, Marshall WF. **Successful treatment of cerebral blastomycosis with voriconazole.** *Clin Infect Dis* 2005; **40**:e69–e71.
153. Perfect JR, Durack DT. **Comparison of amphotericin B and N-D-ornithyl amphotericin B methyl ester in experimental cryptococcal meningitis and *Candida albicans* endocarditis with pyelonephritis.** *Antimicrob Agents Chemother* 1985; **28**:751–755.
154. Liu H, Davoudi H, Last T. **Determination of amphotericin B in cerebrospinal fluid by solid-phase extraction and liquid chromatography.** *J Pharm Biomed Anal* 1995; **13**:1395–1400.